

CASE REPORT

Surgical management of impacted canine: A case series**Akshay Kumar¹, Adrita Nag², Nivedita Jain³, Shruti Bandopadhyay⁴****INTRODUCTION**

When teeth fail to erupt into the oral cavity normally and are impacted, it can affect the dental arch form leading to esthetic and functional challenges. The most commonly impacted teeth are third molars followed by canines.¹

Impacted canines generally present a challenge to the clinician attempting to align the dentition naturally.² Understanding development, incidence and etiology of the impacted canine is important to reach a proper diagnosis and facilitate treatment planning to select the appropriate surgical intervention.

The maxillary canine is considered the second most frequent tooth to be impacted, while the mandibular third molar is the most common.¹ The incidence reported varies between 0.8% to 2.8% for the maxillary canines and 0.2% for the mandibular canines.⁴⁻⁷ Unilateral impaction is five times more common than bilateral cases and the left side is slightly more affected than the right.⁸ Females are more 2.5 times more likely to have impacted canines than males Dachi et al.⁹ in 1961 found the incidence to be 1.17% in females and 0.51% in males. With regard to the position of canine impaction within the arch, the maxillary canine is found in a palatal impaction 85% of the time, versus being in a buccal impaction position (15%).⁴⁻¹⁰ Therefore, early detection, review of family history, clinical examination by age 9-10 years, as well as thorough radiographic assessment is essential in the diagnosis of canine impactions.

The maxillary canine develops in the highest area of the face relative to the rest of the dentition. Therefore, it has an extended development period and the longest path of eruption in the permanent dentition before it reaches its final position. This, amongst other factors, may contribute to the relative increase in frequency of canine impaction. Other factors like arch length

discrepancy and missing lateral incisor may interfere with the guidance of the canine along its path of eruption.¹¹

DIAGNOSIS

Clinical and radiographic assessments are essential tools in evaluating the presence and location of the impacted canine⁴

The clinician must consider the amount of space in the dental arch, morphology and position of adjacent teeth, contours of the bone, mobility of the teeth as well as a radiographic assessment to determine the position of the impacted canine in three dimensions.⁴ Currently, the use of three-dimensional radiographic imaging such cone beam computed tomography (CBCT) is considered to be the diagnostic tool that indicates the most accurate position of the impacted canine in relation to adjacent teeth and it has been suggested to be the standard of care.¹²⁻¹³

METHODS

Thorough clinical and radiographic evaluation is crucial to determine the appropriate method of management of the impacted canine. Many factors must be taken into consideration including confirmation of the impacted canine presence, length and stage of root formation, inclination of the long axis of the tooth, canine apical-coronal position relative to the mucogingival junction (MGJ), buccal-lingual position of the tooth, quantity of bone covering the impacted tooth, and proximity to adjacent teeth.¹²

The available treatment options are surgical removal of impacted canine (along with its associated pathology), or surgical exposure and orthodontic repositioning. Surgical removal of impacted canine was indicated if there was evidence of pathology around the tooth; if there was interference with planned orthodontic treatment; and if there was impingement on adjacent teeth.¹⁴

CASE PRESENTATION

In the current case series, multiple surgical techniques were carefully selected based on the position and extent of the impacted canines in Clove Dental Clinic New Delhi.

-
1. MDS (OMFS), Clove Dental
 2. MDS (Oral Medicine), Zonal Head, Clove Dental
 3. Clinic Head, Clove Dental
 4. Senior Resident, Plastic Burns and Maxillofacial Surgery, Safdarjung Hospital, New Delhi.

Corresponding Author

Dr. Akhsay Kumar, Zonal Oral & Maxillofacial Surgeon, North west Zone, Clove Dental

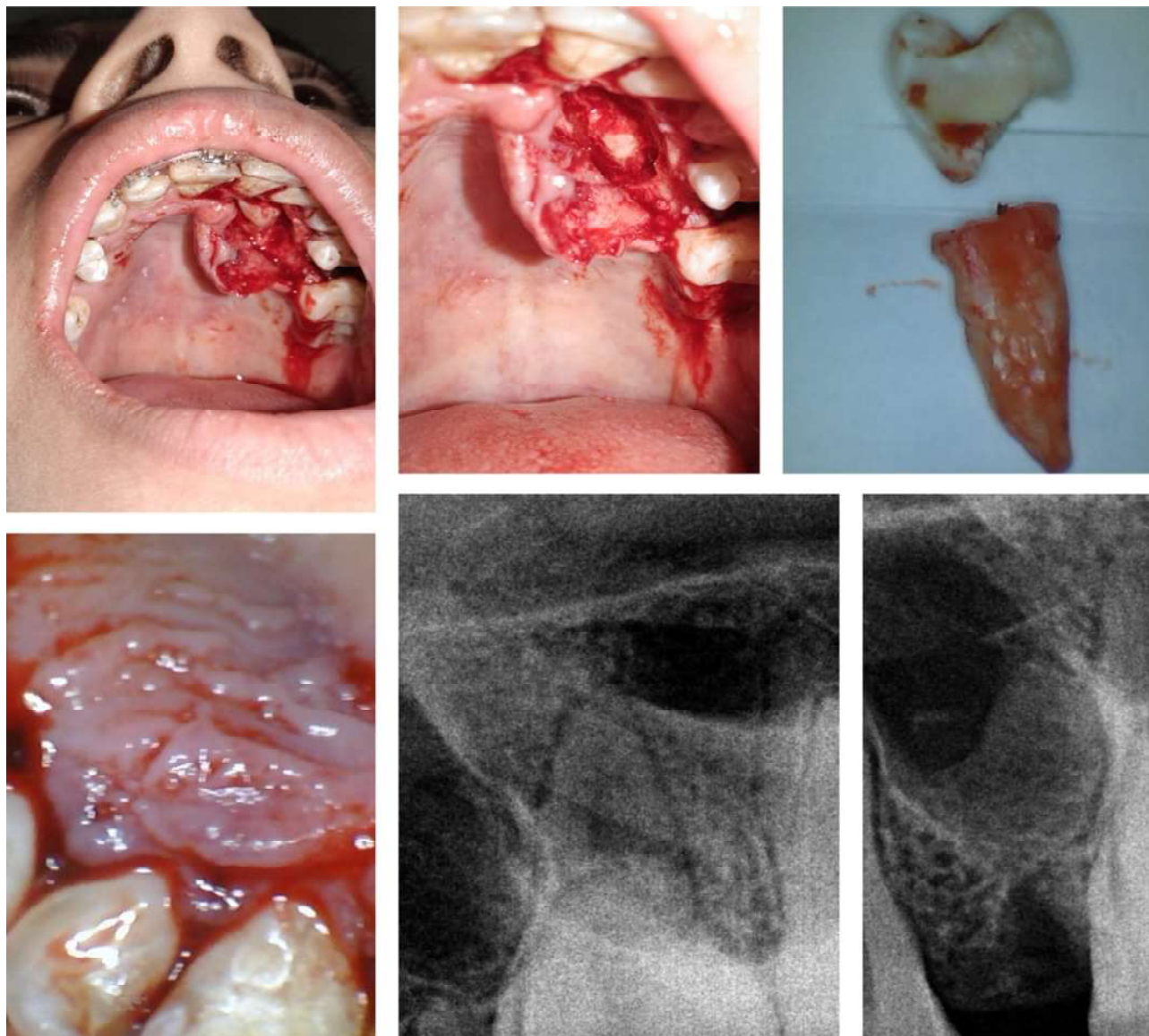


Fig 1: Surgical extraction of palatally impacted canine, tooth sectioning, closure and radiographs

CASE 1

19 year old female patient reported with impacted maxillary canine on left side. Upon thorough investigation using CBCT it was found that the impacted canine was palatally placed horizontally and extended along 22 to 26.(Fig 1) Exposure was done using crevicular incision followed by removal of adequate bone after which the tooth was sectioned into two segments and removed. Closure was done and a custom made palatal splint was provided to the patient for 1week. Patient was kept on regular follow up for 3 weeks after which esthetically pleasant result was achieved and healing was uneventful.

CASE 2

17 year old female patient reported with impacted maxillary canine on left side. Upon thorough investigation

using CBCT it was found that the impacted canine was palatally placed vertically and extended between 21-22 and approximating the maxillary sinus. A crevicular incision was given to gain access followed by removal of adequate surrounding impacted tooth and it was then removed in toto. (Fig 2) Closure was done and a custom made palatal splint was provided to the patient for 1week. Healing was uneventful over follow up for 3 weeks.

CASE 3

35 year old female patient reported with impacted maxillary canine on left side. CBCT revealed that it was palatally placed extending vertically between 22 and 25 with a hooked root approximating nasal floor and maxillary sinus making it a challenging case. Crevicular incision was placed and bone removal was done to expose

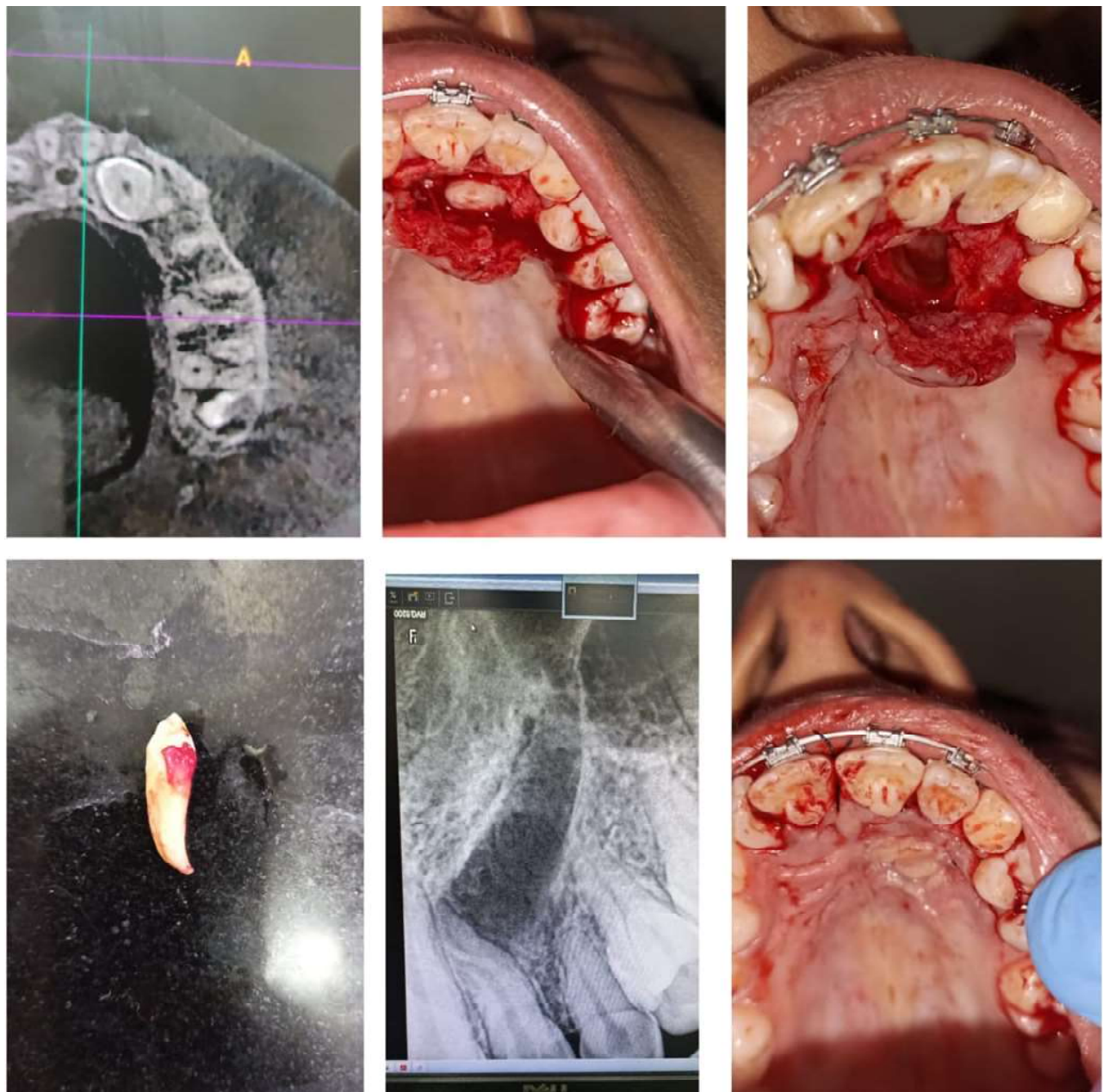


Fig 2: Pre-operative CBCT showing position of palatally impacted canine, surgical extraction, post-operative radiograph and closure of surgical site.

the impacted canine. The crown was removed in multiple sections whereas the root was separated and removed as a whole. (Fig 3) Closure was done and a custom made palatal splint was provided to the patient for 1 week. Esthetically pleasing results were achieved after regular follow ups over 3 weeks.

DISCUSSION

Canine impactions play a significant role in the treatment planning of comprehensive orthodontic care. Canine impactions are more commonly associated with the maxilla than with the mandible. Accord-
ing to

Andreason¹⁵ 85% impactions are palatally located in the maxilla. Surgical exposure and orthodontic repositioning are considered the treatment of choice in most cases wherever it is clinically feasible and a predictable and successful outcome can be obtained. In cases, where exposure and subsequent orthodontic treatment is not indicated, the impacted canine is surgi-cally removed to prevent future problems.

Careful clinical and radiographic examinations are essential to determine the position of the impacted canine and to select the correct surgical interventions to facilitate treatment and achieve favorable results. Cone beam

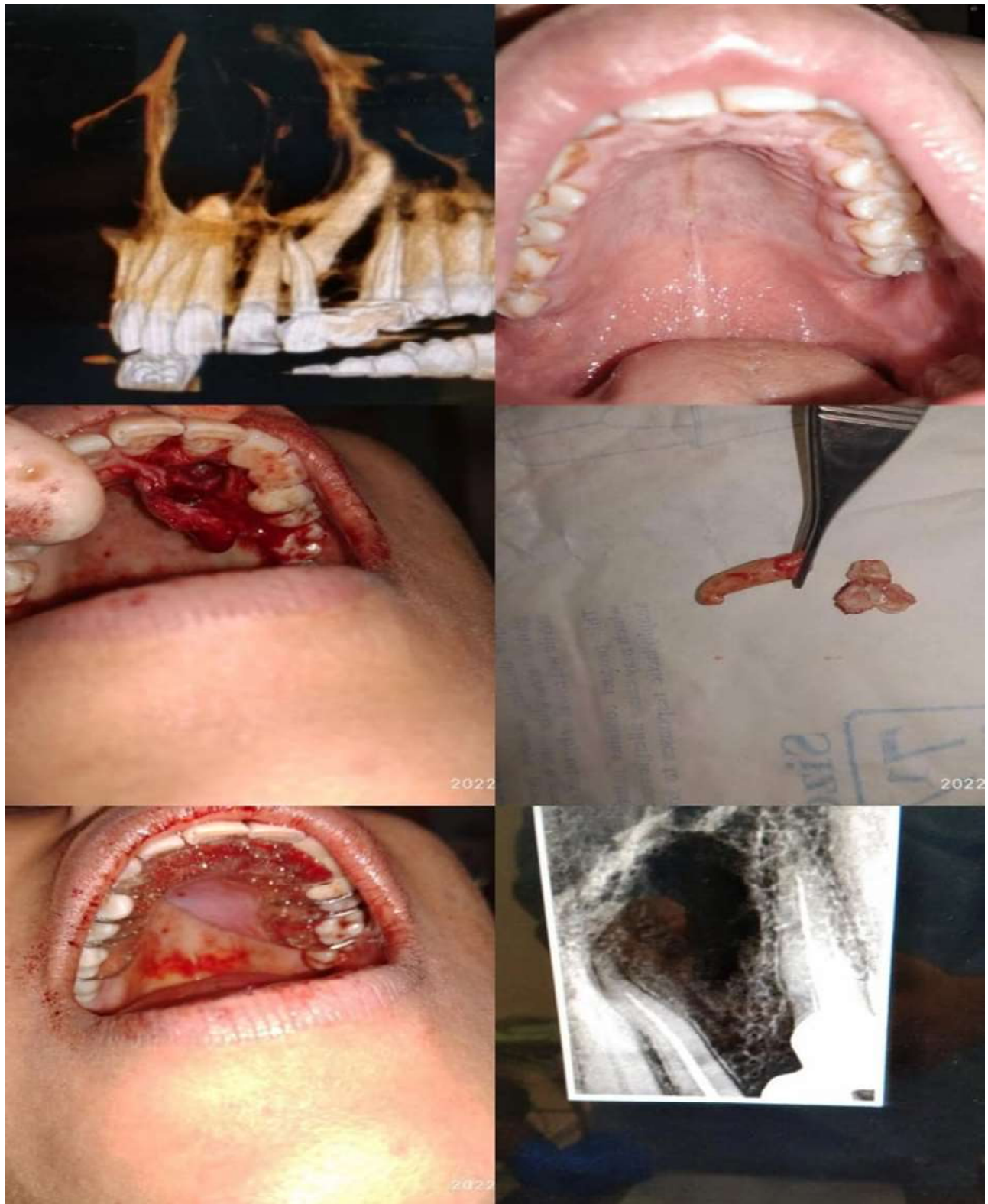

Fig 3: CBCT showing position of palatally impacted canine, clinical picture of surgical site, surgical extraction and tooth sectioning, placement of splint and post-operative radiograph.

computed tomography or conventional radiographs are the most commonly used diagnostic tools to determine the location of the impaction.

The following pathological sequelae associated with tooth impaction have been noted: Dentigerous cyst, odontogenic keratocyst, adenomatoid odontogenic tumor, calcifying epithelial odontogenic (Pindborg)

tumor, odontogenic myxoma, ameloblastoma, external/internal resorption of the impacted tooth, external root resorption of adjacent teeth, transmigration, referred pain and periodontitis. Therefore surgical management is an advisable choice for management.^{7, 11-13}

CONCLUSION

In the current case series, surgical interventions were employed based on the location of the impacted canine allowing proper exposure to proceed with removal of impacted tooth in accordance to priorly planned orthodontic treatment. Esthetically pleasing results were achieved in all cases without infection or surgical complication. The surgical interventions used to expose the impacted canines resulted in satisfactory and stable functional and esthetic results with stable periodontium in the presented cases.

REFERENCES

1. **Bass TB.** Observations on the misplaced upper canine tooth. *Dent Pract Dent Rec.* 1967; 18: 25-33.
2. **Vermette ME, Kokich VG, Kennedy DB.** Uncovering labially impacted teeth: apically positioned flap and closed-eruption techniques. *Angle Orthod.* 1995; 65: 23-32
3. **Zasciurinskiene E, Bjerklin K, Smailiene D, Sidlauskas A, Puisys A.** Initial vertical and horizontal position of palatally impacted maxillary canine and effect on periodontal status following surgical-orthodontic treatment. *Angle Orthod.* 2008; 78: 275-280.
4. **Ericson S, Kurol J.** Radiographic assessment of maxillary canine eruption in children with clinical signs of eruption disturbance. *Eur J Orthod.* 1986; 8: 133-140.
5. **Shah RM, Boyd MA, Vakil TF.** Studies of permanent tooth anomalies in 7,886 Canadian individuals. I: impacted teeth. *Dent J.* 1978; 44: 262-264.
6. **Thilander B, Jakobsson SO.** Local factors in impaction of maxillary canines. *Acta Odontol Scand.* 1968; 26: 145-168.
7. **Thilander B, Myrberg N.** The prevalence of malocclusion in Swedish schoolchildren. *Scand J Dent Res.* 1973; 81: 12-21
8. **Shapira Y, Kufninec MM.** Early diagnosis and interception of potential maxillary canine impaction. *J Am Dent Assoc.* 1998; 129: 1450-1454.
9. **Dachi SF, Howell FV.** A survey of 3, 874 routine full-month radiographs. II. A study of impacted teeth. *Oral Surg Oral Med Oral Pathol.* 1961; 14: 1165-1169.
10. **Rayne J.** The unerupted maxillary canine. *Dent Pract Dent Rec.* 1969; 19: 194-204.
11. **Coulter J, Richardson A.** Normal eruption of the maxillary canine quantified in three dimensions. *Eur J Orthod.* 1997; 19: 171-183.
12. **Mah J, Enciso R, Jorgensen M.** Management of impacted cuspids using 3-D volumetric imaging. *J Calif Dent Assoc.* 2003; 31: 835-841.
13. **Ericson S, Kurol J.** CT diagnosis of ectopically erupting maxillary canines- a case report. *Eur J Orthod.* 1988; 10: 115-121.
14. **Chawla S,** Impacted canines: our clinical experiences *Int J Clin Pedia Dent,* September-December 2011;4(3):207-212
15. **Andreason, JO.; Peterson, JK.; Laskin, DM.** Textbook and color atlas of tooth impactions. Copenhagen: Munksgaard Publishers, 1997. pp. 544.