

CASE REPORT

VESTIBULAR INCISION WITH SUBPERIOSTEAL TUNNEL ACCESS (VISTA) TECHNIQUE USING CONNECTIVE TISSUE GRAFT: A CASE REPORT

Ipshita Narayan¹

The present report covers a case of recession coverage done for multiple contiguous teeth in upper anteriors. The procedure involved is known as vestibular incision with subperiosteal tunnel access (VISTA). It's a minimally invasive procedure involving tunneling and coronal repositioning of gingiva. Additionally, we have used connective tissue graft (CTG) to augment the thickness of gingiva. Both procedures were selected to increase patient comfort and help achieve complete recession coverage. The result presented postoperatively is favorable and necessitates further long-term studies to evaluate efficacy of such procedures in a variety of cases.

INTRODUCTION

Recession is defined as the apical migration of gingiva below the cemento-enamel junction.¹ This obviously entails an esthetic issue for the patient, especially if such a migration occurs in the front tooth. Apart from esthetics, recession may lead to root caries or sensitivity of teeth. Treatment involves recession coverage, a surgical procedure which may involve use of graft from the patient's own mouth. Understandably, such extensive procedures are not welcomed by patients. Patients instead demand procedures which are minimally invasive and highly effective. Thus, favoring VISTA (vestibular incision with subperiosteal tunnel access) technique.²

The technique in question involves giving a single incision in the maxillary frenum. Using this as access to the underlying tissues, tunneling is done over the bone surface freeing the periosteum from the bony attachments. Now, this freely mobile tissue is coronally repositioned and recession is covered.

The chief advantage of this technique is its ease, and the ability to cover recession of multiple contiguous teeth together. Additionally, the thickness of soft tissue can be further improved using connective tissue graft, again a procedure which doesn't leave an open wound

in the patient's mouth. This paper aims to report one such case and its treatment outcome.

CASE REPORT

A 39-year-old male came to the Department of Periodontics with a chief complaint of tooth sensitivity in the upper anteriors (Fig. 1). There was no significant medical or family history and patient had no habits. Clinical examination revealed Millers class 1 gingival recession in multiple contiguous teeth from 13 to 21. There was presence of adequate keratinized gingiva and good vestibular depth. The initial visit of the patient involved scaling and root planing. Multiple oral hygiene instructions were given post procedure, and then she was recalled after a week for the recession coverage technique.

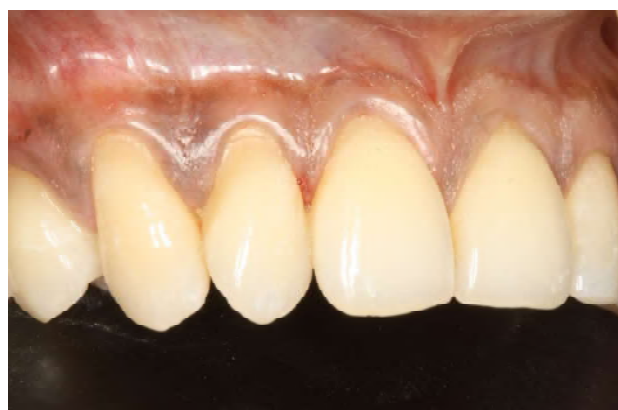

Fig. 1: Preoperative view

After one week, VISTA technique was done under local anesthesia. Firstly, an incision was given in the region of frenum using a no. 11 blade (Fig. 2). This vestibular incision provided access to the entire upper arch. Next, a tunnel was created subperiosteally using a periosteal elevator (Fig. 3). The approach to the subperiosteal region was gained through the vestibular incision. Sufficient tunneling was done to facilitate easy coronal repositioning of the gingiva without creating tension in the whole soft tissue complex. Thus, the tunnel was created from tooth 24 to tooth 14 well beyond its mucogingival junction. This was further extended to the interpapillary regions.

1. Consultant Periodontist, Clove Dental, Gurgaon

Corresponding Author

Ipshita Narayan

Consultant Periodontist, Clove Dental, Gurgaon

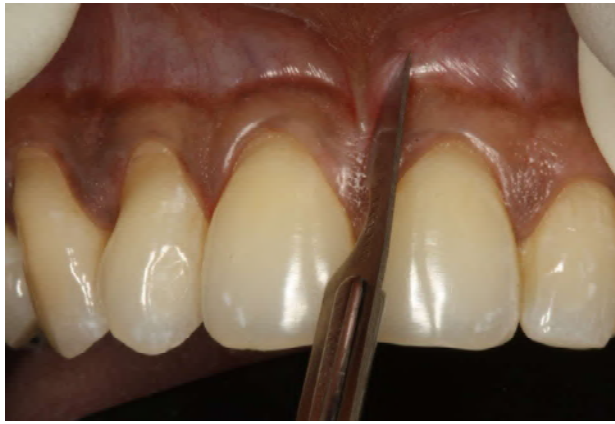

Fig. 2: Vestibular Incision

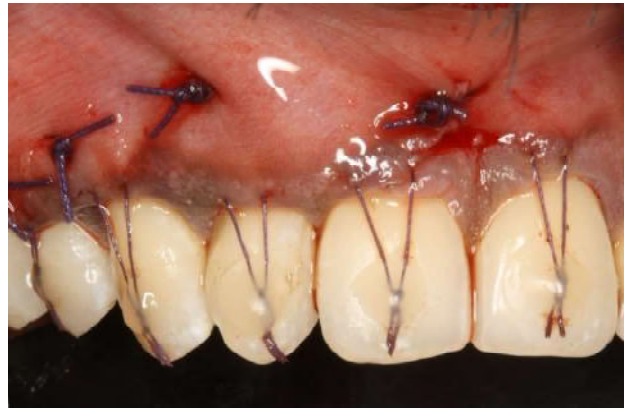

Fig. 5: Suturing done

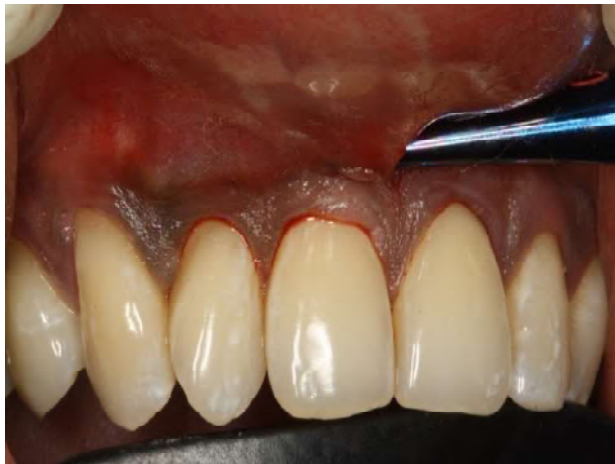

Fig. 3: Subperiosteal tunnel created

Having prepared the recipient site, connective tissue graft of appropriate size was harvested from the palate distal to the premolar region (Fig. 4). Glandular tissue remnants were removed from the graft. The graft was then tucked into the prepared tunnel. Care was taken to ensure it extended well beyond the site of recession. Along with the gingival complex, it was advanced coronally and held in position with a composite button on labial aspect of tooth. Coronally anchored sutures (expanded PolyTetraFluoroEthylene sutures; 5-0) were attached to these buttons and cured. (Fig. 5) Periodontal dressing was placed over the site.

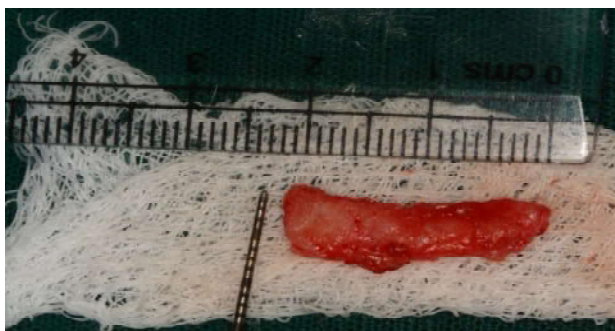


Fig. 4: Connective tissue graft harvested

Post-operative instructions included strict oral hygiene maintenance and restrictions to be followed over the next 2 weeks. Patient was instructed to come back after 2 weeks for suture removal.

DISCUSSION

Gingival recession poses functional and esthetic problem for the patient. Recession may be caused by mechanical trauma, chemicals or even poor oral hygiene. One of the predisposing factors is the thickness of gingiva, with thin translucent gingiva being more prone to recession defects.³ Thus, along with recession coverage, its occasionally required to thicken the gingiva so that recession doesn't recur.

Here, we have treated multiple recession defects using VISTA technique with connective tissue graft(CTG). This procedure was introduced in 2011 by HH Zadeh.² The technique introduces broader access and single incision methodology into tunneling procedures. VISTA is a minimally invasive procedure offering numerous advantages. It involves giving a full thickness incision in the frenal area and through it, gaining access to the subjacent gingival complex subperiosteally. Since the incision is made in the frenum, the first obvious advantage of this technique is better esthetics and no-show of incisions when the patient walks out of the clinic. Secondly, incision given in frenum tends to tear lesser as compared to the highly technique sensitive intrasulcular incisions of other tunneling procedures. Thirdly, multiple teeth can be treated using a single incision resulting in better patient experience intra and post-operatively.²

Connective tissue graft is harvested here to improve gingival thickness. As suggested by previous authors, connective tissue can be considered the gold standard procedure in terms of recession coverage.⁴ Harvesting connective tissue eliminates an open wound in the palate vis-à-vis free gingival graft and hence improves patient's

experience. An additional advantage of using CTG with a coronally repositioned flap is an increase in the width of attached gingiva, as corroborated by earlier authors.⁵ Placement of this graft into the tunnel prepared also ensures increased vascularity and graft perfusion. Perfect color matching is yet another advantage of using CTG.⁶

Suturing the gingiva coronally using horizontal mattress suturing technique provides recession coverage and stability to the graft-gingiva complex. Gravity additionally ensures stability of gingival margin in this location with minimum reversal post-operatively.⁷ Composite buttons placed labially on tooth surface act as anchors here.

Follow-up done after 6 months (Fig. 6) reveals recession coverage and an overall decrease in teeth sensitivity. Thus, the treatment outcome is said to be favorable with minimum discomfort to patient.

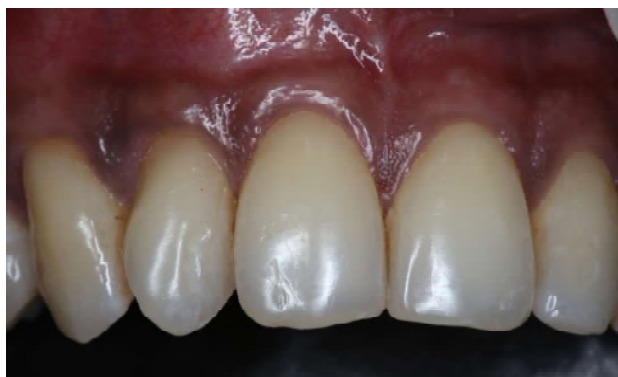

Fig. 6: Post operative 6 month

CONCLUSION

The present case demonstrates successful recession coverage in multiple teeth using minimally invasive VISTA technique. This procedure eliminates the need for an extensive surgery with multiple incisions, thus increasing patient comfort and decreasing fear associated with such coverage procedures. Long-term follow-up studies need to be done for a variety of cases, to better understand the success rate of this technique.

REFERENCES

1. **Oates TW, Robinson M, Gunsolley JC.** Surgical therapies for the treatment of gingival recession. A systematic review. *Ann Periodontol.* 2003;8:303–20
2. **Zadeh HH.** Minimally invasive treatment of maxillary anterior gingival recession defects by vestibular incision subperiosteal tunnel access and platelet-derived growth factor BB. *Int J Periodontics Restorative Dent.* 2011;31:653–60.
3. **Seba Abraham, K.T. Deepak, R. Ambili, C. Preeja, V. Archana** - Gingival biotype and its clinical significance – A review. *The Saudi Journal for Dental Research.* 2014;5(1):3-7.
4. **Chambrone L, Chambrone D, Pustiglioni FE, Chambrone LA, Lima LA.** Can subepithelial connective tissue grafts be considered the gold standard procedure in the treatment of Miller Class I and II recession-type defects?. *J Dent.* 2008;36(9):659-671.
5. **Edel A.** Clinical evaluation of free connective tissue grafts used to increase the width of keratinised gingiva. *J Clin Periodontol* 1974;1:185-96
6. **Raofi S, Asadinejad SM, Khorshidi H.** Evaluation of Color and Width of Attached Gingiva Gain in Two Surgical Techniques: Free Gingival Graft and Connective Tissue Graft Covered By Thin Mucosal Flap, a Clinical Trial. *J Dent (Shiraz).* 2019;20(4):224-231.
7. **Soni N, Sikri P, Kapoor D, Soni BW, Jain R.** Evaluation of the efficacy of 100% Type-I collagen membrane of bovine origin in the treatment of human gingival recession: A clinical study. *Indian J Dent* 2014;5:132-8