

## ORIGINAL ARTICLE

# AUTOLOGOUS PRP WITH AND WITHOUT CALCIUM SULPHATE $\beta$ -HEMIHYDRATE IN TREATMENT OF PERIODONTAL OSSEOUS DEFECTS: A RANDOMISED CLINICAL TRIAL

VB Mandlik<sup>1</sup>, Manab Kosala<sup>2</sup>

## ABSTRACT

**Background:** Platelet Rich Plasma (PRP) is an autologous source of concentration of growth factors found in platelets, which on degranulation release various growth factors that play a vital role in healing. The objective of the present study was to assess the efficacy of Autologous Platelet Rich Plasma with and without Calcium Sulphate  $\beta$ - Hemihydrate in resolution of osseous defects. **Method:** A total of 100 subjects in the age group of 30 to 50 years, diagnosed with chronic periodontitis, with bilateral osseous defects, probing pocket depth  $\geq 6$  mm and osseous defect  $\geq 3$  mm as observed on clinical and radiographic examination (intraoral periapical radiograph). In one site Group - A (test group), calcium sulphate  $\beta$  - hemihydrate with autologous platelet rich plasma was placed in the defect, in contra lateral site Group - B (control group) only calcium sulphate  $\beta$ - hemihydrate was placed in the osseous defect. **Results:** Un-paired *t*-test was used for comparing the two sets of data at baseline for all parameters between Group - A and Group - B, and all the parameters were found to be statistically insignificant ( $p > 0.05$ ). The changes in each variable did not follow normal distribution, thus change in each variable was analyzed using a non-parametric test (Mann-Whitney test). Both the groups exhibited clinical improvement in all parameters at the end of the study except for resolution of osseous defect. The resolution of osseous defect (Osseous gain) was higher in Group - A subjects, as compared to Group - B ( $P < 0.05$ ). **Conclusion:** The percentage of resolution of osseous defect (Osseous gain) was higher in Group - A (53.79%) as compared to Group - B (46.02%).

**Keywords:** Bone grafts, Periodontal osseous defects, Platelet Rich Plasma, Calcium Sulphate  $\beta$ - Hemihydrate

1. Zonal Clinical Head, Clove Dental, Pune
2. Associate Professor, Dept of Dental Surgery, Armed Forces Medical College, Pune

### Corresponding Author

VB Mandlik

Zonal Clinical Head, Clove Dental, Pune

## INTRODUCTION

Periodontitis is a result of extension of gingival inflammation in to the supporting tissues resulting in pocket formation, attachment loss and creation of osseous defects which may ultimately result in loss of tooth. The ultimate goal of periodontal therapy is not only to halt the disease process, but also to restore the attachment apparatus lost as a result of periodontal disease. In an effort to achieve periodontal regeneration, various biomaterials and biological agents have been tried either alone or in combinations with varying degree of success.<sup>1-4</sup> In an attempt to make regenerative treatment affordable, calcium sulphate  $\beta$ - hemihydrate is being used alone or with platelet rich plasma (PRP).

Calcium sulphate  $\beta$ - hemihydrate has been used extensively over a period of time as a graft material. It is inexpensive, biocompatible and completely resorbs following implantation into the defect.<sup>5</sup> Platelet-rich plasma (PRP) refers to an increased concentration of autologous platelets in a small amount plasma, PRP contains high concentration of various growth factors that play an important role in the healing process.<sup>6</sup>

The current study was carried out to compare the efficacy of calcium sulphate  $\beta$ - hemihydrate alone or in combination with PRP in management of periodontal osseous defects.

## MATERIAL AND METHOD

The minimum sample size was calculated at Confidence Interval = 95%,  $\alpha$  error of 5%, power of test 80%. The sample size worked out to be 93 subjects, therefore, 100 subjects were enrolled for the study.

A total number of 100 subjects in the age group of 30 to 50 years, diagnosed with chronic periodontitis, with bilateral periodontal osseous defects, with pocket depth  $\geq 6$  mm and osseous defect  $\geq 3$  mm as seen on intraoral periapical radiographs were included in the study. Subjects with systemic diseases and pregnant or lactating females were excluded from the study. Ethical clearance was obtained from Ethical Committee of Armed Forces Medical College, Pune and the patients enrolled in the study were explained the purpose of study and written consent was obtained from each patient. A split mouth

design was used. At the time of surgery, the defects were randomly assigned to either test group (calcium sulphate  $\beta$ -hemihydrate with autologous platelet rich plasma) or control group (calcium sulphate  $\beta$ -hemihydrate only).

The following parameters were recorded: Probing Pocket depth (PPD), Clinical Attachment Level (CAL), Gingival Recession (GR), Plaque Index (PI), Gingival Index (GI), at baseline, three, six and nine months respectively and osseous defect (OD) (Osseous Gain) was assessed at baseline, six and nine months respectively.

The entire procedure of preparing PRP (Fig.1) was followed as per the guidelines of Aron Gonshor.<sup>7</sup> In one site Group - A (test group) (Fig. 2) calcium sulphate  $\beta$ -hemihydrate with PRP was filled in the osseous defect, and in contra lateral site Group - B (control group) (Fig. 3) osseous defect was filled with calcium sulphate  $\beta$ -hemihydrate only.

Following local anesthesia, undisplaced flap was raised by giving a cervicular incision. The incision was extended one tooth mesial and one tooth distal of the


osseous defect for better visibility and accessibility. On exposure of the defect granulation tissue was removed, scaling and root planning was done by using hand instruments to remove calculus if any, so as to obtain a smooth root surface. After debridement, the defect was irrigated with saline.

In Group - A subjects, Calcium sulphate  $\beta$ -hemihydrate mixed with PRP was placed in to the osseous defect. The flap was then positioned back to the original level. Primary closure was achieved by giving interrupted loop sutures. Coe-pack was applied and patients were called for removal of sutures after 2 weeks.

In Group - B subjects, the graft material was mixed with saline and applied to the defect site. The flap was closed, sutured and Coe-pack was placed.

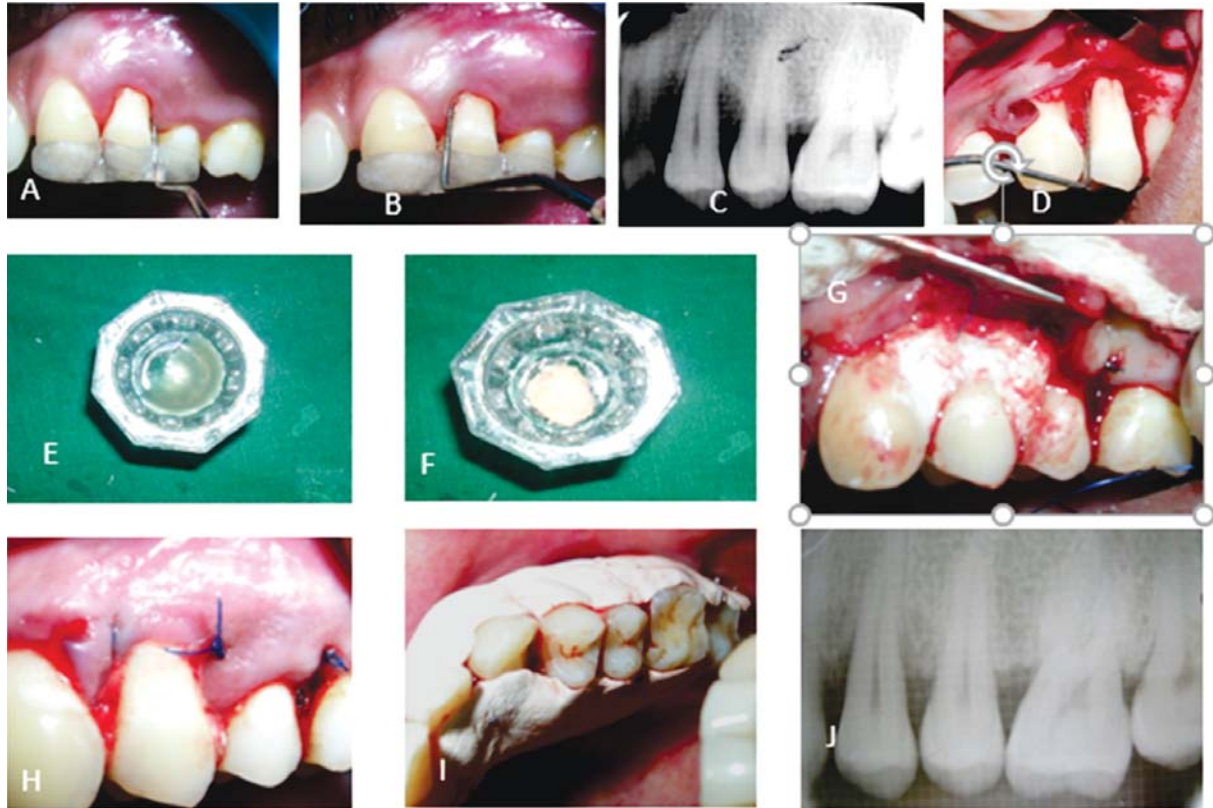
All subjects were administered antibiotic and anti-inflammatory medication for five days. Recall was done at three, six and nine months, respectively. Radiographic assessment was done at six and nine months respectively. All the parameters were tabulated and statistical evaluation was carried out.

**Fig.1: Preparation of Platelet Rich Plasma**



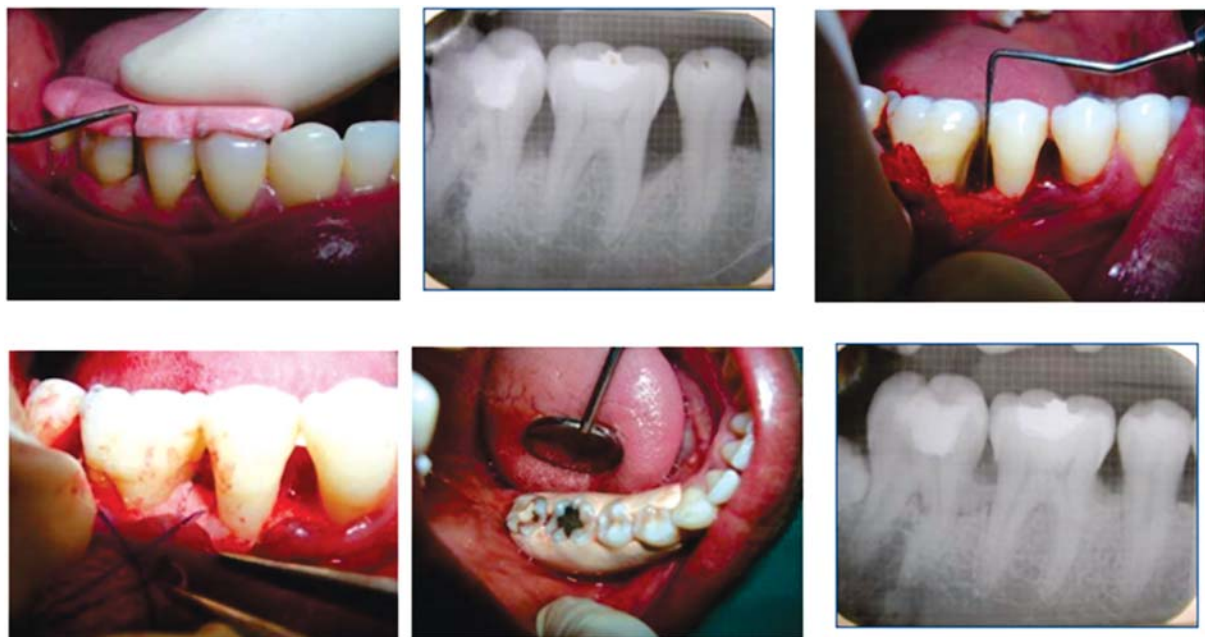
**Fig. A)** Collection of Blood, **B)** Blood transferred in test tube containing anticoagulant, **C)** First spin at 1300 rpm for 10 min, **D)** Cell separation (Buffy coat), **E)** Platelet Poor Plasma aspirated in another test tube, **F)** Second spin at 2000 rpm for 10 min, **G)** Supernatant serum with PRP at base of test tube, **H)** 10% calcium chloride, **I)** Thrombin power, **J)** Platelet Rich Plasma, **K)** Platelet Rich Plasma mixed with Calcium sulphate  $\beta$ -hemihydrate

**Fig. 2: Group - A: Calcium sulphate  $\beta$ - hemihydrate with autologous platelet rich plasma**



**Fig. 2: A & B) Pre-operative probing pocket depth, C) Pre-operative IOPA showing Osseous defect, D) Defect Exposed and degranulated, E) Platelet Rich Plasma, F&G) Calcium sulphate  $\beta$ - hemihydrate mixed with platelet rich plasma and placed into the defect, G) Suture Placed, H) Periodontal dressing placed, I) IOPA at 270 days showing partial resolution of defect.**

**Fig. 3: Group - B: Calcium sulphate  $\beta$ - hemihydrate alone**



**Fig. 3: A) Pre-operative probing pocket depth, C) Pre-operative IOPA showing Osseous defect, C) Defect Exposed and degranulated, D) Calcium sulphate  $\beta$ -hemihydrate and placed into the defect, E) Suture Placed and Periodontal dressing placed, I) IOPA at 270 days showing partial resolution of defect.**

**RESULTS**

Un-Paired t - test was used for comparing the two sets of data at baseline for all parameters between Test group and Control group and all the parameters were found to be statistically insignificant ( $p > 0.05$ ) (Table 1).

**Table 1: Baseline comparison of all measurements (in mm) between groups**

Parameters	GROUP	Mean	Std. Deviation	't'	'p'
Probing Depth (mm)	A	7.39	0.852	1.089	.277NS
	B	7.26	0.836		
Clinical Attachment Level (mm)	A	7.28	.830	.966	.335NS
	B	7.17	.779		
Gingival Recession (mm)	A	.20	.471	.320	.750NS
	B	.18	.411		
Osseous Defect (mm)	A	3.63	.720	.193	.847NS
	B	3.65	.744		
Plaque index	A	.99	.190	.731	.467NS
	B	1.01	.192		
Gingival Index	A	1.07	.212	.704	.482NS
	B	1.05	.189		

Significant reduction in PPD, CAL, OD, PI and GI were noted in both the groups. Post operative GR was observed in test as well as in control groups (Table 2). The changes in each variable did not follow normal distribution, thus, change in each variable were analyzed using non-parametric test (Mann-Whitney test).

It was observed that, Group - A (Test group) showed significant difference in resolution of osseous defect (Osseous Gain) as compared to Group - B at the end of nine months ( $P < 0.05$ ) (Table 3). Rest all parameters were statically insignificant ( $P > 0.05$ ) in both the groups.

**DISCUSSION**

The ultimate goal of periodontal therapy has always been the regeneration of lost attachment apparatus. Currently, there are various treatment modalities available for periodontal regeneration, which includes various biomaterials, biological agents either alone or in combination.<sup>1,2,6,8-10</sup> In an effort to reduce cost of periodontal therapy, Calcium sulphate  $\beta$ - Hemihydrate either alone or in combination with PRP was tried in the current study.

Calcium Sulfate  $\beta$ - hemihydrate has been used as bone graft for over 100 years in field of medicine. It is

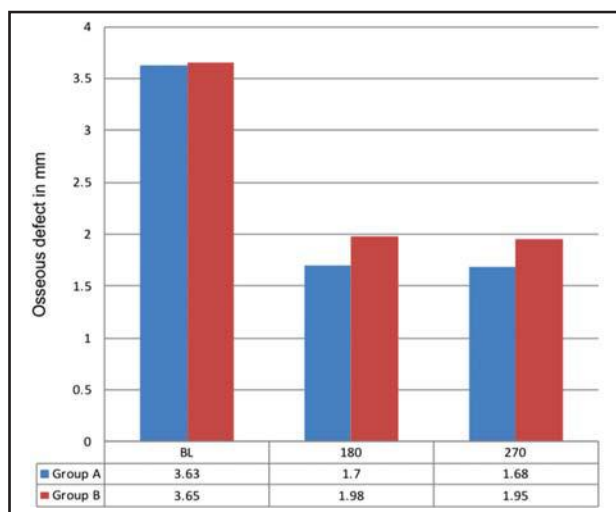
**Table 2: Comparison of parameters in Group - A and Group - B at Baseline and at 270 days**

Parameter	No of Subjects	Period	Mean	SD	't'	'p'	Mean	SD	't'	'p'
Probing Depth (mm)	100	Base Line	7.39	0.852	52.632	.000	7.26	0.836	55.864	.000
		270 days	2.20	.402			2.27	.446		
Clinical Attachment Level (mm)	100	Base Line	7.28	.830	54.626	.000	7.17	.779	54.669	.000
		270 days	2.15	.359			2.24	.429		
Gingival Recession (mm)	100	Base Line	.20	.471	-13.349	.000	.18	.411	-13.552	.000
		270 days	1.10	.560			1.19	.581		
Osseous Defect (mm)	100	Base Line	3.63	.720	32.914	.000	3.65	.744	27.953	.000
		270 days	1.68	.601			1.97	.577		
Plaque index	100	Base Line	1.07	.212	15.749	0.000	1.05	.189	4.654	0.000
		270 days	.66	.120						
Gingival Index	100	Base Line	.99	.190	16.816	0.000	1.05	.201	21.117	0.000
		270 days	.63	.089			.62	.099		

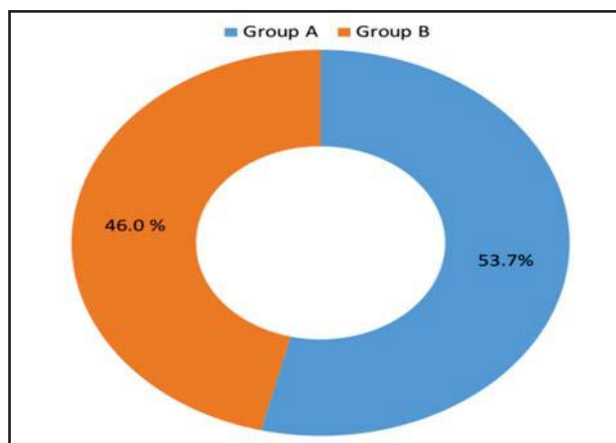
**Table 3: Comparison of change in a parameter - Between groups  
(Change at 270 days compared to baseline), Mann-Whitney Non-Parametric Test**

	GROUP	Mean Rank	Sum of Ranks	U	'p'
Probing Depth (mm)	A	106.97	10696.50	4353.5	0.104NS
	B	94.04	9403.50		
Clinical Attachment Level (mm)	A	107.67	10767.00	4283.0	.070NS
	B	93.33	9333.00		
Gingival Recession (mm)	A	17.88	304.00	138.0	.803NS
	B	17.12	291.00		
Osseous Defect (mm)	A	116.45	11644.50	3405.5	.000 Significant
	B	84.56	8455.50		
Plaque index	A	93.06	9305.50	4755.5	.578NS
	B	107.95	10794.50		
Gingival Index	A	102.68	10268.00	4782.0	.594NS
	B	98.32	9832.00		

**Graph 1: Change in Osseous Defect in both the Groups (in mm)**



**Graph 2: Change in Percentage of Osseous Gain in both the Groups at 270 days**



biocompatible, bioabsorbable, osteoconductive biomaterial and has been used as bone graft that resorbes within 45 to 76 days following implantation.<sup>11,12</sup>

PRP is basically an increased concentration of platelets in plasma obtained after centrifugation of blood. It contains high concentration of growth factors which are biological mediators that play an important role during in regulating cell proliferation, chemotaxis and differentiation of cells, which in turn, promote healing of periodontal tissue.<sup>13,14</sup>

Platelets play an important role in hemostasis. The growth factors stored in  $\alpha$  - granules are platelet-derived growth factor (PDGF), transforming growth factor -  $\beta$  (TGF- $\beta$ ), Insuline like growth factor (IGF) and vascular endothelial growth factor (VEGF). These factors are released as a result of degranulation of  $\alpha$ - granules which may be caused by variety of stimuli. Release of these factors increases the angioblasticfibroblastic proliferation which results in formation of granulation tissue and also aids in remodeling of extracellular matrix. there by aiding in wound healing.<sup>14</sup>

Melcher (1976)<sup>15</sup> was the first to describe the concept of periodontal regeneration. He suggested the role of various cellular components of attachment apparatus and concluded that if cells from periodontal ligament are allowed to repopulate the defect, true regeneration was possible. Later Karring and Nyman (1980)<sup>16</sup> studied the mechanism of periodontal healing and concluded that stimulation of progenitor cells to occupy defect is essential for periodontal regeneration. Keeping in mind the vital role of growth factors, PRP was used in the present study.

The possibility of using autologous PRP along with bone grafting procedures was first explored by Marx et al<sup>17</sup> where they observed that addition of PRP to bone graft accelerates the rate of bone formation and maturation as compared to bone graft alone.

Combination of PRP and bone substitutes for the treatment of periodontal osseous defects is based on a sound biologic rationale; however, the clinical results of different studies indicative of the synergistic effect of PRP remain equivocal.<sup>17-22</sup>

The present study was carried out to evaluate the efficacy of calcium sulphate  $\beta$ - hemihydrate alone or in combination with PRP, in terms of reduction in PPD, change in CAL and resolution of OD (Osseous gain). The baseline parameters in both the groups were comparable (Table 1). Both groups showed OD fill (Osseous gain), mild GR, and improvement in GI and PI between baseline and nine months (Table 2).

The improvement in PI and GI in both the Groups may be due to better patient compliance following periodontal therapy. PPD is not only an important parameter in diagnosing periodontitis but also in evaluating the outcome of periodontal therapy. There was a significant reduction in PPD within both test and control group from baseline to 9 months period (Table 2). However, there were no significant difference in reduction of pocket depth when two groups were compared ( $p>0.05$ ) (Table 3) the results of the present study are in accordance with other studies.<sup>23,24</sup>

A more reliable way to assess the outcome of periodontal therapy is CAL. Our observation for CAL is in accordance with other studies.<sup>21-25</sup> The gain in the CAL in both the groups was due to resolution of gingival inflammation and regeneration of the lost periodontium.<sup>26,27</sup> Post operatively GR was observed in both the groups and was due to post-operative shrinkage of tissues (Table 2).

The rationale for using PRP was to accelerate vascularization of the graft, enhance soft tissue healing and bone regeneration. The fibrin meshwork in PRP acted as glue aiding in stabilizing the graft material and the blood clot. It also prevent the apical migration of epithelial cells and connective tissue cells from the flap, and thus may have exerted GTR like effect in the treated defects.

The mean amount of OD fill (Osseous gain) from baseline to 9 month in Group - A and Group - B was 1.95 mm and 1.68 mm respectively, which was statistically significant (Table 2, Graph 1). However, inter group comparison showed that the resolution of defect in Group A was more as compared to Group - B subjects ( $P<0.05$ ) (Table 2). Our observations are in line with studies of other authors.<sup>20,26,28</sup>

The mean change in percentage of defect fill from baseline to 9 month was significantly greater in Group - A (53.70%) when compared to Group - B (46.30%) (Graph 2).

The greater amount of bone fill in Group - A subject may be due to the beneficial effect of PRP during healing. It has been reported that PRP "jump starts", the healing by providing increased levels of growth factors at the local site, works well in combination with the graft, aids in early consolidation of graft at defect site, helps to speeds up the mineralization process and increases the trabecular density. Our observation for resolution of OD (Osseous gain) are in line with other studies.<sup>14,20,26</sup> Autologous PRP is safe to use. Due to its sticky nature it improves the handling of graft material and makes packing of graft in to the defect much easier. It also maintains space for regeneration.<sup>28</sup>

From the observation of the present study it can be speculated that Calcium sulphate  $\beta$ - hemihydrate with PRP was able to regenerate more bone. This was probably due to the fact that multiple biological agents are released by activation of platelets and their presence in high concentration at the defect site may have helped in early consolidation of graft.

## LIMITATIONS OF STUDY

Histological study which is a gold standard for assessment for regenerative procedure was not done because of certain limitations and ethical considerations.

## CONCLUSION

The result of the present study is encouraging and supports the clinical use of PRP with calcium sulphate  $\beta$ - hemihydrate. It is recommended that a multicentric study should be carried on a larger sample size to substantiate our findings.

## FINANCIAL AID

This study has been financed by research grant from office of the DGAFMS.

## REFERENCES

1. **Carranza FA.** Clinical Periodontology. 10<sup>th</sup> ed. 2006. p. 968-990.
2. **Lindhe J.** Clinical periodontology and implant dentistry. Lang NP, Karring T, editors. Oxford: Blackwell Munksgaard; 2003 Jun.
3. **Rosen PS, Reynolds MA, Bowers GM.** The treatment of intrabony defects with bone grafts. Periodontology 2000. 2000 Feb;22(1):88-103.

4. **Thomas MV, Puleo DA, Al-Sabbagh M.** Calcium sulfate: A review. *J Long Term Eff Med Implants.* 2005; 15(6): 599-607
5. **Mandlik VB, Roy S, Jha AK.** Comparative evaluation of bioglass with calcium sulphate  $\beta$ -hemihydrate for the treatment of intraosseous defects-a clinico-radiological study. *Medical Journal Armed Forces India.* 2012 Jan 1;68(1):42-7.
6. **Marx RE.** Platelet-Rich Plasma: A Source of Multiple Autologous Growth Factors for Bone Grafts. In: Lynch SE, Genco RJ, Marx RE. *Tissue Engineering: Applications in Maxillofacial Surgery and Periodontics.* Chicago: Quintessence Publishing Co, Inc. 1999; 9: 71-82.
7. **Gonshor A.** Technique for producing platelet-rich plasma and platelet concentrate: Background and process. *International J Periodontics Restorative Dent.* 2002 Dec 1;22(6).
8. **Mukherji A, Rath SK.** Calcium sulfate in periodontics: A time tested versatile alloplast. *Journal of the Scientific Society.* 2016 Jan 1;43(1):18.
9. **Zeichner-David M.** Regeneration of periodontal tissues: cementogenesis revisited. *Periodontology 2000.* 2006 Jun;41(1):196-217.
10. **Gottlow J, Nyman S, Lindhe J, Karring T, Wennström J.** New attachment formation in the human periodontium by guided tissue regeneration Case reports. *Journal Clin Periodontol.* 1986 Jul;13(6):604-16.
11. **Tay BK, Patel VV, Bradford DS.** Calcium sulfate–and calcium phosphate–based bone substitutes: mimicry of the mineral phase of bone. *Orthopedic Clinics.* 1999 Oct 1;30(4):615-23.
12. **Peltier LF.** The use of plaster of Paris to fill defects in bone. *Clinical Orthopaedics and Related Research®.* 1961 Jan 1;21:1-31.
13. **Carlson NE, Roach Jr RB.** Platelet-rich plasma: clinical applications in dentistry. *The J Am Dent.* 2002 Oct 1;133(10):1383-6.
14. **Anila S, Nandakumar K.** Applications of platelet rich plasma for regenerative therapy in periodontics. *Trends Biomater Artif Organs.* 2006;20(1):78-83.
15. **Melcher AH.** On the repair potential of periodontal tissues. *J Periodontol.* 1976 May;47(5):256-60.
16. **Karring T, Nyman S, Lindhe J.** Healing following implantation of periodontitis affected roots into bone tissue. *J Clin Periodontol.* 1980 Apr;7(2):96-105.
17. **Marx RE, Carlson ER, Eichstaedt RM, Schimmele SR, Strauss JE, Georgeff KR.** Platelet-rich plasma: Growth factor enhancement for bone grafts. *Oral Surg Oral Med Oral Pathol Oral Radiol Endod.* 1998; 85: 638 - 646.
18. **Robert EM.** Platelet rich plasma: Evidence to support its use, *J Oral Maxillofac Surg.* 2004; 62: 489-496.
19. **Hanna R, Trejo PM, Weltman RL.** Treatment of intrabony defects with bovine-derived xenograft alone and in combination with platelet-rich plasma: A randomized clinical trial. *J Periodontol.* 2004 Dec;75(12):1668-77.
20. **Okuda K, Tai H, Tanabe K, Suzuki H, Sato T, Kawase T et al.** Platelet-rich plasma combined with a porous hydroxyapatite graft for the treatment of intrabony periodontal defects in humans: A comparative controlled clinical study. *Journal of periodontology.* 2005 Jun;76(6):890-8.
21. **Demir B, Sengün D, Berberoglu A.** Clinical evaluation of platelet-rich plasma and bioactive glass in the treatment of intra-bony defects. *Journal of clinical periodontology.* 2007 Aug;34(8):709-15.
22. **Ozdemir B, Okte E.** Treatment of intrabony defects with beta-tri-calcium phosphate alone and in combination with platelet-rich plasma. *J Biomed Mater Res B appl Biomater.* 2012; 100(4): 976-83.
23. **Orsini M, Orsini G, Benloch D, Aranda JJ, Lazaro P, Sanz M, De Luca M, Piattelli A.** Comparison of calcium sulfate and autogenous bone graft to bioabsorbable membranes plus autogenous bone graft in the treatment of intrabony periodontal defects: A split-mouth study. *J Periodontol.* 2001 Mar;72(3):296-302.
24. **Piemontese M, Aspriello SD, Rubini C, Ferrante L, Procaccini M.** Treatment of periodontal intrabony defects with demineralized freeze-dried bone allograft in combination with platelet-rich plasma: A comparative clinical trial, *J Periodontol.* 2008; 79(5): 802-10.
25. **Khosropanah H, Shahidi S, Basri A, Houshyar M.** Treatment of Intrabony Defects by DFDBA Alone or in Combination with PRP: A Split-Mouth Randomized Clinical and Three-Dimensional Radiographic Trial. *J Dent (Tehran).* 2015; 12(10): 764-73.
26. **Ouyang XY, Jing Q.** Effect of platelet-rich plasma in the treatment of periodontal intrabony defects in humans. *Chinese medical journal.* 2006 Sep 1;119(18):1511-21.
27. **Saini N, Sikri P, Gupta H.** Evaluation of the relative efficacy of autologous platelet-rich plasma in combination with  $\beta$ -tricalcium phosphate alloplast versus an alloplast alone in the treatment of human periodontal intrabony defects: a clinical and radiological study. *Ind J Dent Res.* 2011 Jan 1;22(1):107.
28. **Sanchez AR, Sheridan PJ, Kupp LI.** Is platelet-rich plasma the perfect enhancement factor? A current review. *Int J Oral Maxillofac Implants.* 2003; 18: 93-103.