

CASE REPORT**CASE REPORT OF A CASE OF POST-COVID MUCORMYCOSIS**Anshu Agrawal¹, Ritika Singh², S. S. Pandey³**ABSTRACT**

Coronavirus has been the cause of global pandemic. It has presented with complex clinical manifestation that healthcare is still recovering from it and searching for definite cure in process. However, the infection has resulted in depressed immune response where the some treatment protocols like use of immunosuppressive drugs have also resulted in reduced immune response. All this have allows the opportunistic infections to grow and cause severe manifestations. Especially in severely infected cases or those with preexisting comorbidities are at greater risk. Here, a case report is presented where a patient reported to dental clinic with complain of dental pain post recovery and hospitalization due to COVID-19. Treatment was started as defined protocol. Gradually the patient develop palatal swelling and investigation pointed towards Mucormycosis infection.

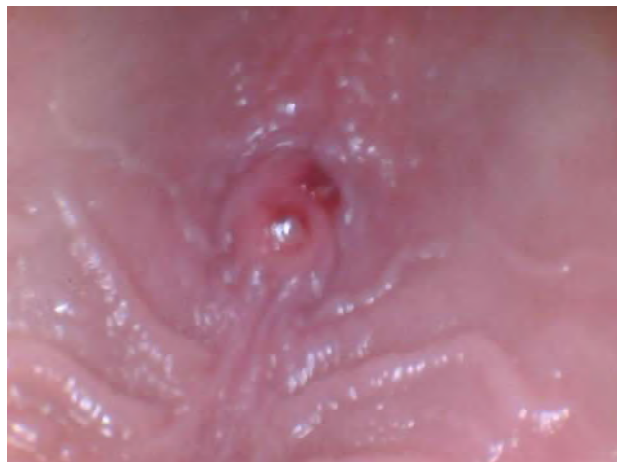INTRODUCTION

Coronavirus disease 2019 (COVID -19) has dominated the year 2020. The disease, though spread by infection of Severe Acute Respiratory Syndrome – Coronavirus 2 (SARS-COV-2), has reported of several complicating feature related to disease outcome, treatment protocol and challenges to the healthcare. The illness has more severely affected the individuals suffering from comorbidities like diabetes, cardiovascular diseases, obesity and hypertension.¹ Estimated 5-30% infected patients get severely ill and require ICU care.² As the COVID-19 treatment protocol still depend on SOLIDARITY trials, subsequently there is reduced immune response either due to previous morbidities or due to multi-drug pharmacotherapy being employed. Hence invasive fungal infection have been common due to compromised state of health due to COVID-19. This

case report presents encounter with Mucormycosis in a COVID-19 patient post recovery.

CASE REPORT

A 57-year old male reported to Clove Dental Clinic in Bodakdev, Ahmedabad (India) on October 24, 2020 with chief complaint of severe pain in maxillary arch since 10 days. Anamnesis revealed, patient has been suffering from diabetes. Patient was positive for SARS-COV-2 infection earlier, for which he was hospitalized on October 09, 2020 and discharged with stable hemodynamic conditions on October 18, 2020. During treatment he was given Inj. Sitaxin 30M, Inj. Fragmin (5000) Solumedrol 40mg, Inj. Clexane (0.6) BD, Tab Crocin, Tab PAN D, Vitamin C, Tab Zinc, Cap Quente D3. On oral examination, tenderness on percussion was seen with tooth numbers 21, 22 and 23 was seen; porcelain-fused to metal (PFM) bridge was present on tooth numbers 23-25 and root stump with 25. Intra-oral periapical radiograph showed periapical changes in the region; hence, root canal treatment (RCT) was advised irt 21 and 22 as part of elective treatment. Reverse-transcriptase polymerase chain reaction (RT-PCR) test was advised for COVID-19. On third day, as the RT-PCR test report was found negative, and access openings for 21 and 22 were done. During treatment, a 3cmx3cm small firm swelling on the middle of hard palate with no pus discharge was also noticed (Fig 1). On fourth day, gingival abscess with thick, yellow pus discharge from gingival sulcus irt 11 and 21 was seen (Fig 2). Based on IOPA radiograph and pus discharge

**Fig. 1: Initial palatal swelling**

-
1. Consultant Endodontist, Clove Dental, Ahmedabad
 2. Zonal Clinical Head, Clove Dental, Ahmedabad
 3. HOD, Oral and Maxillofacial Surgery and Implantologist, Clove Dental

Corresponding Author**Dr. Anshu Agrawal**

Consultant Endodontist

Clove Dental, Bodakdev, Ahmedabad, India

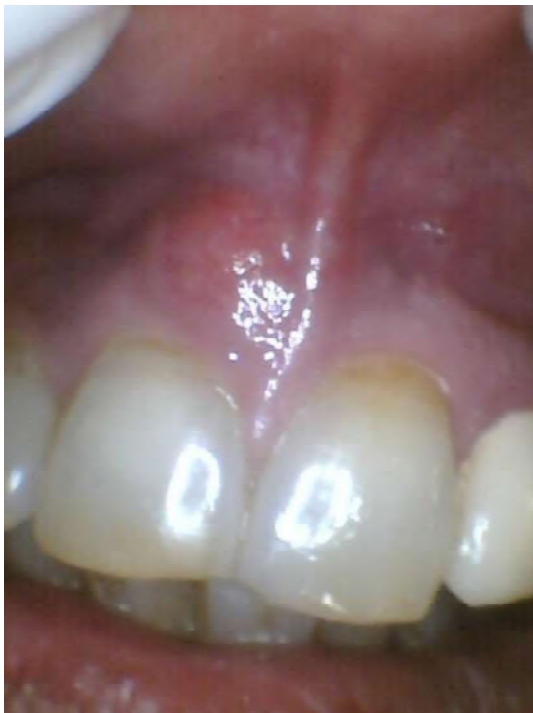

Fig. 2: Gingival abscess with 11 and 21

an endo-perio lesion was suspected. Access opening of 11 did not show pus discharge from root canal, hence deep scaling was planned for periodontal infection. However, scaling was accompanied with severe pain and there was no bone resistance felt on scaler tip. Palatal swelling was further enlarged in comparison; hence, CBCT of maxillary arch was advised (Fig 3). CBCT report showed congestion of maxillary sinus (Fig 4). Clinical and radiological presentation were suggestive for Mucormycosis. Further consultation with the otolaryngologist confirmed the diagnosis of Mucormycosis infection. Antifungal drugs were commenced immediately. However, CBCT report on

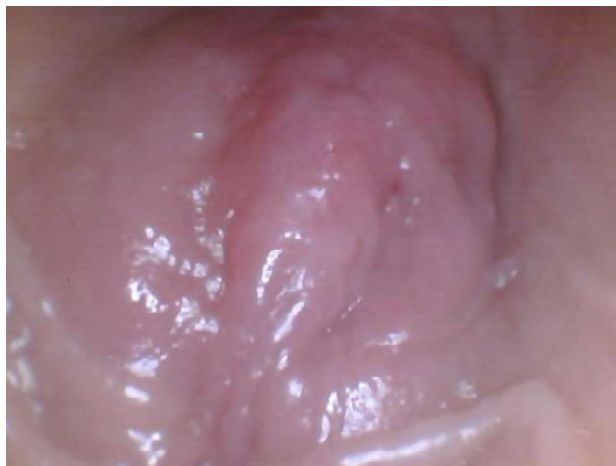

Fig. 3: Increased palatal swelling on recent appointment

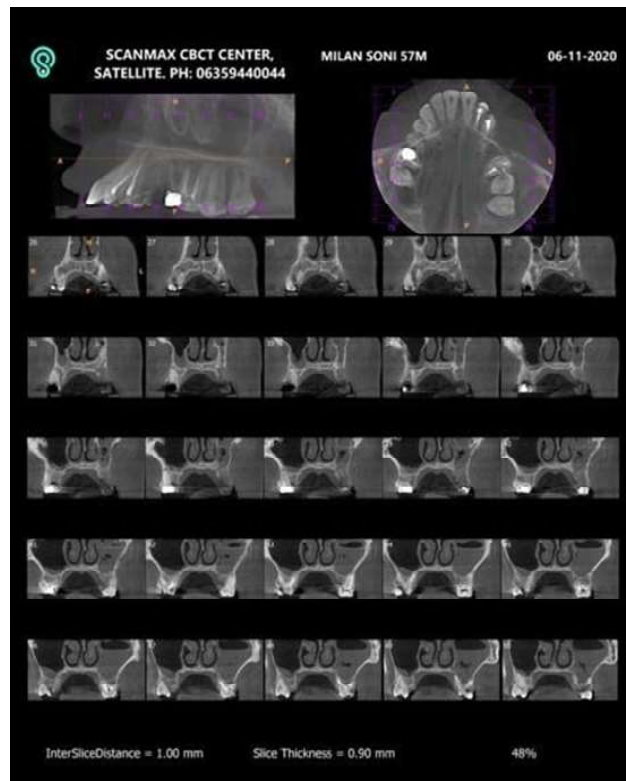


Fig. 4: CBCT findings as congestion of right side maxillary sinus

December 10, 2020 shows further erosion of bone extending to palatal and orbital floor, necessitating immediate surgical intervention and debridement. The patient is still under treatment since last reported.

DISCUSSION

The first case of coronavirus was reported on November 17, 2019 in the Wuhan City, Hubei Province, China.³ Since then the infection has found its route to the global population due to globalization and has emerged as a pandemic. SARS-COV-2 is only the 8th coronavirus discovered causing primarily respiratory symptoms as others. It is in the line of zoonotic diseases, whereby 2.5 billion cases with 2.7 million deaths are reported every year worldwide.⁴ The coronavirus has shown to complicate the presenting clinical manifestations. The complexities have been attributed to preexisting diseases, use of immunosuppressive pharmacotherapy, potential risk of hospital-acquired infections, and the diminishing effect of COVID-19 on systemic immune response. In a recent report, 8% patients have shown to have hospital-acquired secondary fungal and bacterial infections.⁵ COVID-19 alter the innate immunity by reducing the CD4+ and CD8+ cell, T lymphocytes.⁶

Mucormycosis is a rare opportunistic invasive fungal infections which is being reported as post-COVID

complications among others. The mucormycetes hyphae invade the vasculature causing host tissue infarction and necrosis.⁴ Rhino-orbital-cerebral infection is the most common clinical manifestation, likely due to spore inhalation into paranasal sinuses.^{4,5} Heretofore, Mucormycosis was most commonly associated with diabetes and corticosteroid use among other conditions like neutropenia, stem cell transplant, immunocompromised individuals and hematologic malignancies.⁴ In present case as well three factors were common as diabetes, use of corticosteroids for COVID-19 treatment and likely suppressed immune response due to coronavirus. Mehta et al. reported very similar case of rhino-orbital Mucormycosis, where patient was 60-yr old male, having diabetes and was treated with methylprednisolone and enoxaparin as given in this case along with dexamethasone (not given in this case) and supportive care. Two other cases reported for COVID-19 associated Mucormycosis by Werthman-Ehrenreich (orbital compartment syndrome) and Pasero et al (pulmonary Mucormycosis) showed pre-existing hypertension.^{4,6} Werthman-Ehrenreich reported Mucormycosis even after coverage by Amphotericin B.⁴ All three patients in reported studies died during treatment.

As per newspaper, recently several cases across India has been reported for COVID associated Mucormycosis. Sir Ganga Ram Hospital, New Delhi reported 13 cases of COVID-triggered Mucormycosis where 5 patients died during treatment.⁷ Max Superspeciality hospital in New Delhi reported 24 cases where 20 patients lost their eyesight.⁸ Ahmedabad Civil Hospital, Ahmedabad, Gujrat, registered at least 44 such cases claiming 9 lives.⁹ In Mumbai, Andheri's Kokilaben Hospital reported 6 cases since August out of which 4 died, and RN Cooper hospital, Juhu reported 25 cases since 9 months (50% jump from previous year) and death of 20% patients.¹⁰

Mucormycosis has overall incidence rate of 0.005-1.7, fatality rate of 46%.⁴ It is difficult to diagnose and its prognosis is poor even with early diagnosis and surgical and medical intervention. COVID-19 has provided favorable condition for co-infection. Hence it is very important to diagnose it the earliest. Song et al suggested a pathway for diagnosis and therapy of invasive fungal co-infection.¹¹ This case was reported as a delayed complication post hospital discharge at a dental office suggesting: 1) Mucormycosis can be late complication related to COVID-19 unlike other cases which were hospital based; and 2) dentist being at the forefront of oral disease diagnosis and treatment are likely to encounter such case on the basis of sinusitis as initial symptoms, which may extend to painful, necrotic ulcerations and perforation of hard palate.¹²

CONCLUSION

The novel coronavirus disease 2019 has unveiled an urgent threat to global health whereby high number of infections have been reported rendering variable clinical manifestations. This is the latest in the history of pandemics which have and subsequently will potentially impact the global health and economy in long terms. The post-COVID complications are still under study for its variable aspects. As the healthcare is struggling to provide definite care for COVID-19, advent co-infections like Mucormycosis signify grave implications in form of immunosuppression by disease and pharmacotherapy being opportunity to invade and infect. Hence, severe COVID-19 cases are at high risk and should be kept for longer follow-up following discharge.

BIBLIOGRAPHY

1. **Sampson V, Kamona N, Sampson A.** Could there be a link between oral hygiene and the severity of SARS-CoV-2 infections?. *British dental journal.* 2020 Jun;228(12):971-5.
2. **Pemán J, Ruiz-Gaitán A, García-Vidal C, Salavert M, Ramírez P, Puchades F, García-Hita M, Alastruey-Izquierdo A, Quindós G.** Fungal co-infection in COVID-19 patients: Should we be concerned?. *Revista iberoamericana de micología.* 2020 Apr 1;37(2):41-6.
3. **Harapan H, Itoh N, Yufika A, Winardi W, Keam S, Te H, Megawati D, Hayati Z, Wagner AL, Mudatsir M.** Coronavirus disease 2019 (COVID-19): A literature review. *Journal of Infection and Public Health.* 2020 Apr 8
4. **Werthman-Ehrenreich A.** Mucormycosis with orbital compartment syndrome in a patient with COVID-19. *The American Journal of Emergency Medicine.* 2020 Sep 16.
5. **Unnikrishnan R, Misra A.** Infections and diabetes: Risks and mitigation with reference to India. *Diabetes & Metabolic Syndrome: Clinical Research & Reviews.* 2020 Sep 22.
6. **Mehta S, Pandey A.** Rhino-Orbital Mucormycosis Associated With COVID-19. *Cureus.* 2020 Sep;12(9).
7. **Pasero D, Sanna S, Liperi C, Piredda D, Branca GP, Casadio L, Simeo R, Buselli A, Rizzo D, Bussu F, Rubino S.** A challenging complication following SARS-CoV-2 infection: a case of pulmonary mucormycosis. *Infection.* 2020 Dec 17:1-6.
8. **Mint.** COVID-19 triggering rare, deadly fungal infection, claims Delhi hospital. Available from: <https://www.livemint.com/news/india/covid-19-triggering-rare-deadly-fungal-infection-claims-delhi-hospital-11607966032401.html>. [Accessed 24th December 2020]
9. **National Herald.** COVID cases linked 'black fungus infection' appears across Delhi hospitals. Available from: <https://www.nationalheraldindia.com/health/covid-cases-linked-black-fungus-infection-appears-across-delhi-hospitals>. [Accessed 24th December 2020]
10. **Business Today.** After COVID-19, a deadly fungal infection strikes Ahmedabad, kills 9 Available from: <https://>

www.businesstoday.in/current/economy-politics/after-covid-19-a-deadly-fungal-infection-strikes-ahmedabad-kills-9/story/425335.html. [Accessed 24th December 2020]

11. **Sumitra Debroy.** Fungal infection proves deadly for some patients post-Covid. Available from: <https://timesofindia.indiatimes.com/city/mumbai/fungal-infection-proves-deadly-for-some-patients-post-covid/articleshow/79808382.cms>. [Accessed 24th December 2020]
12. **Song G, Liang G, Liu W.** Fungal co-infections associated with global COVID-19 pandemic: a clinical and diagnostic perspective from China. *Mycopathologia*. 2020 Jul 31:1-8.
13. **Dan M.** Mucormycosis of the head and neck. *Current Infectious Disease Reports*. 2011 Apr 1;13(2):123-31.