

CASE REPORT**NON-VITAL BLEACHING- A CASE REPORT****Ritu Rana¹, Monaliza²****ABSTRACT**

Discolored anterior tooth may be a common aesthetic concern for several patients. It can have an intense effect on their self-esteem, confidence, interaction with others and employability. Successful management of the discolored endodontically treated tooth are often performed using bleaching agents like sodium perborate, Hydrogen Peroxide (H₂O₂) etc. Proper selection of the bleach and appropriate bleaching technique has resulted within the conservative and successful management of the cases of discolored teeth. The choice of technique is critical so as to bring the desired results because improper technique can cause cervical resorption and eventually loss of teeth. The aim of this case report is to explain the proper management of a discolored anterior tooth after endodontic treatment.

INTRODUCTION

The presence of front discolored tooth may be of profound concern for some patients and lead them to look for professional dental advice or treatment. In such cases of anterior discolored tooth which is non vital but the structurally intact the treatment of choice should be endodontic treatment with minimal access cavity preparation and doing intra-coronal bleaching. This approach is minimally invasive than complete ceramic, ceramic fused to metal, or veneers, which removes more amount of tooth structure, resulting to irreversible damage and are expensive.

Intra-coronal bleaching is well documented within the literature¹. It's an efficient and safe procedure, although it's been related to particular level of risk, which incorporate cervical root resorption (CRR). The exact mechanism of CRR isn't fully known. Previous studies indicate that previous traumatic injury, the patient's age, and a high concentration of H₂O₂ together with heating appear to be risk factors that promote cervical root resorption²⁻³.

-
1. Consultant Endodontist
Clove Dental, Gurgaon Zone
 2. Centre Head
Clove Dental, Model Town, Delhi

Corresponding Author**Ritu Rana**

Consultant Endodontist, Clove Dental, Gurgaon Zone

Email: riturana2013@gmail.com

The denouement of the procedure depends on the correct identification of etiology, diagnosis and arrant execution of bleaching technique. Case selection plays a very crucial role in bringing the desired results of the bleaching procedure. Careful evaluation of the tooth and surrounding tissues is vital for the success of the bleaching.

The tooth requires to possess healthy surrounding periodontal tissues, a properly obturated canal, and most of all, a properly positioned barrier so as to prevent leakage of the bleaching agent into the periapical tissues⁴.

CASE REPORT

A 32 years old female patient complained discoloration of her maxillary left central incisor (Fig. 1,8). History of trauma 12 years back. No relevant medical history and history of allergy noted.

Patient was explained about the RCT followed by bleaching procedure and composite build up to correct the discoloration and fracture respectively. Informed written consent was obtained from the patient.

The treatment of the tooth started with the rubber dam isolation, then with the help of pumice and slurry the tooth surface was cleaned, used VITA shade guide for recording the shade. RCT completed (Fig. 2,3,4). After obturation, 2 mm Gutta plug was removed from the coronal portion of root below the CEJ using round bur. The prepared coronal portion of the root sealed with 1mm glass ionomer cement packed over the gutta percha (Fig. 5).

The pulp chamber etching done with 37% phosphoric acid followed by washing and drying. The etching washing and drying is done to open the dentinal tubules which in turn is responsible for the effective activity of the bleaching agent. Following this, mixing of 38% H₂O₂ (pola office ultradent, USA), bleaching agent done into thick paste and immediately placed into the pulp chamber with the help of a spatula instrument and properly condensed with a wetted cotton pellet (Fig. 6).

Access cavity was sealed with Glass-ionomer cement as a temporary core material. This was intimated to the patient that the procedure includes some risk of fracture in consecutive appointments so she should avoid eating

hard foods and chew with caution during the treatment. The bleaching agent was re-placed after every week for three weeks. Three rounds of H₂O₂ treatment produced satisfactory color improvement (Fig. 7).

Reliable bond strength of bleached dental hard tissues are often achieved after 2 weeks. It had been during this point that the colour of the bleached tooth stabilized and a calcium hydroxide dressing was placed within the pulp chamber so as to buffer the low pH level which will occur on cervical root surfaces after intra-coronal application of bleaching agents.

Composite core build up done (Fig. 9).

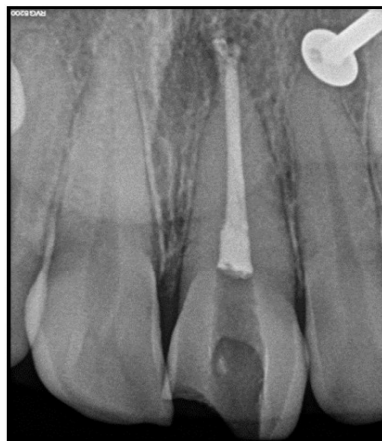

Fig. 4: Obturation

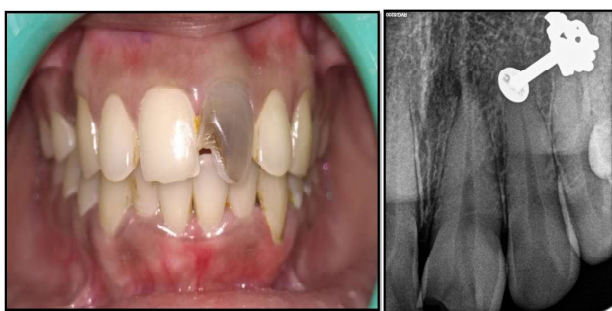


Fig. 1(a and b): Pre-op

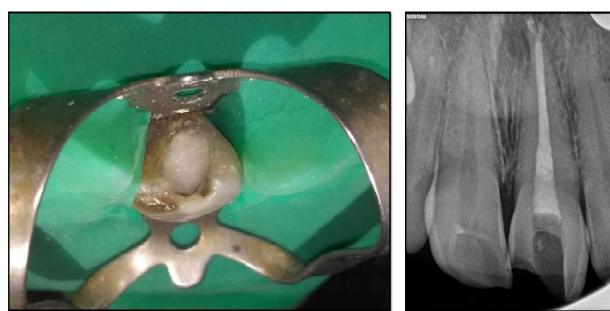


Fig. 5 (a and b): Placement of GIC Barrier

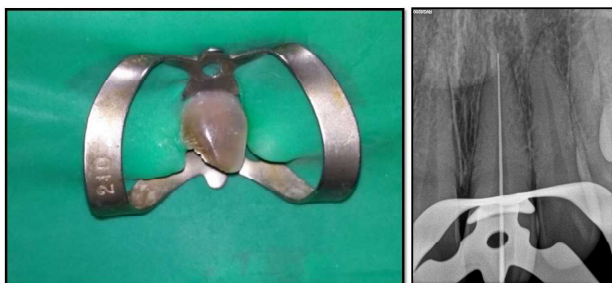


Fig. 2 (a and b): Working Length

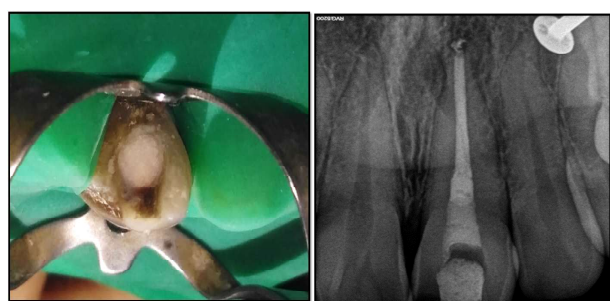

Fig. 6 (a and b): Placement of Bleaching agent

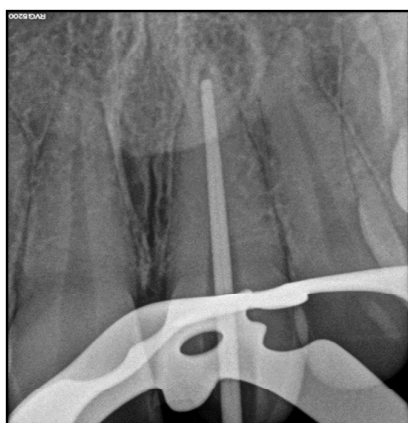

Fig. 3: Master Cone X-ray

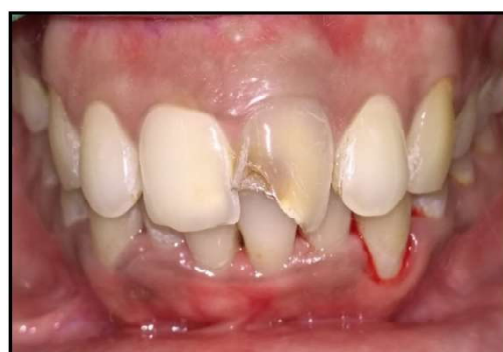

Fig. 7: Post Bleaching

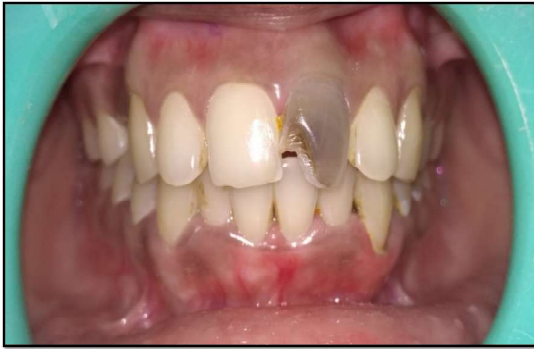

Fig. 8: Pre-op

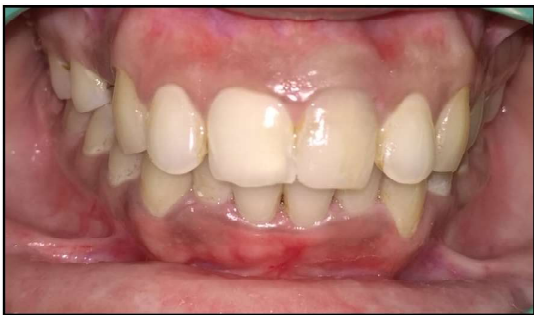

Fig. 9: Post-op

DISCUSSION

There are different treatment options available for managing discolored teeth. The management includes full veneers, laminates, crowns, and non-invasive technique like bleaching. Even though, laminate veneer or a full porcelain crown is one of the most predictable methods of managing such cases but it involves natural tooth material loss. Although laminate veneer is relatively conservative alternative to crown, it may mask the discoloration but this procedure has the disadvantage of fracture, debonding and marginal leakage, along with that it requires tooth preparation and is irreversible⁵.

In contrast Non-vital bleaching overweigh the rest of choices as it is a noninvasive procedure more economical, and less time-consuming.

The intrinsic discoloration is caused due to pigmentation that consists of long chain organic molecule. Pola office containing light activated 38% hydrogen peroxide was utilized in the present procedure. This dental bleach is well-documented⁶⁻⁷. Hydrogen peroxide releases oxygen that breaks down conjugated bonds related to the stains into a single bond, which later are often washed out with water and hence can effectively remove the stains.

This process results in more absorption of colored wavelengths, leading to tooth whitening effect.

It is well documented in some previous studies one reference mention here also that rate of success of treatment of anterior non vital teeth with or without crown shows no significant difference⁸, Thus, supporting our view that endodontically treated anterior teeth do not require crowns⁹.

CONCLUSION

The case presented depicts the effectiveness of the non-vital bleaching using H₂O₂ along with water to achieve predictable esthetic outcome. The case was followed up for 1.5 years with no signs and symptoms of relapse of the discoloration or cervical root resorption. Hence, it can be concluded that walking bleaching technique using H₂O₂ can be used as a treatment of choice for non-vital, discolored traumatic cases.

REFERENCES

1. **Meyenberg KH.** Non-vital teeth and porcelain laminate veneers—a contradiction? *Eur J Esthet Dent.* 2006;1(3):192-206.
2. **Rotstein I, Friedman S, Mor C, et al.** Histological characterization of bleaching-induced external root resorption in dogs. *J Endod.* 1991;17(9):436-441.
3. **Lado EA, Stanley HR, Weisman MI.** Cervical resorption in bleached teeth. *Oral Surg Oral Med Oral Pathol.* 1983;55(1):78-80.
4. **Baba NZ.** Contemporary Restoration of Endodontically Treated Teeth: Evidence-Based Diagnosis and Treatment Planning. Chicago, IL: Quintessence Publishing Co. Inc.; 2013.
5. **Goldstein CE, Goldstein RE, Feinman RA, Garber DA.** Bleaching vital teeth: State of the art. *Quintessence Int.* 1989;20:729-37.
6. **Poyser NJ, Kelleher MG, Briggs PF.** Managing discoloured non-vital teeth: The inside/outside bleaching technique. *Dent Update.* 2004;31:204.
7. **Gallagher A, Maggio B, Bowman J, Borden L, Mason S, Felix H.** Clinical study to compare two in-office (chairside) whitening systems. *J Clin Dent.* 2002;13:219-24.
8. **Sorensen JA, Martinoff JT.** Clinically significant factors in dowel design. *J Prosthet Dent.* 1984;52:28-35.
9. **Goerig AC, Mueninghoff LA.** Management of the endodontically treated tooth. Part I: Concept for restorative designs. *J Prosthet Dent.* 1983;49:340-5.