

CASE REPORT

REHABILITATION OF CRANIAL DEFECT USING PMMA CRANIAL IMPLANT

Rakesh Dhiman¹, Rahul Bahri², Pearl Bahri Dhiman³

INTRODUCTION

Cranial defects may be derives from congenital or acquired causes secondary to trauma or surgery. Bony calvaria is a protective encasing that shields the underlying sensitive brain tissue. General indications for cranioplasty include painful and pulsating defects, danger of trauma to the underlying brain tissue, deforming and unesthetic defects and symptoms like headache pain, or tenderness at the defect site.¹ Defects may involve any part of cranium including frontal, temporal, parietal, occipital or temporal bone. Reconstruction of composite defects may require osteoplastic reconstruction in form of autografts such as cranium, tibia, ribs, scapula, fascia, sternum and others, xenografts or alloplastic implants including Heat acrylized polymethylmethacrylates, polyethylene, metals like titanium or tantalum, silicones, ceramics like cortoss, hydroxyapatite or newer materials like poly ether-ether ketones.^{2,3,4} An ideal material must possess properties like it must ensure complete closure of the defect, should be radiolucent, resistant to infections, should be dimensionally stable and not leach any by-products, should be easy to fabricate and provide scope for easy modification, easy to use and economically inexpensive.³ Recent advances include use of CAD/CAM technology and 3D printing for digital fabrication of cranial defect.⁵

Rehabilitation involves a multidisciplinary team comprised of neurosurgeon, craniofacial rehabilitation specialist and maxillofacial prosthodontist. The aim of rehabilitation is to restore the anatomic continuity, esthetics, improve cerebral blood flow, cerebrovascular reserve capacity and alleviate neurological symptoms that may be a consequence of unrestricted and unprotected brain tissue.⁶ This case report highlights the fabrication and surgical placement of PMMA heat acrylized cranial implant in a patient with frontotemporoparietal discontinuity defect secondary to trauma.

1. MDS (Prosthodontics)
2. MDS (Prosthodontics)
3. BDS (peardhi@yahoo.co.in)

Corresponding Author

Brig (Dr) Rakesh Dhiman

MDS (Prosthodontics), G M Strategic Projects, Clove Dental

Email: rakesh.dhiman@yarrowdentallabs.com

CASE REPORT

A 29 years old serving soldier was referred from department of neurosurgery for fabrication of alloplastic heat acrylized PMMA cranial implant of left side. History revealed that patient had met with a road traffic accident 06 months back causing fracture of frontotemporoparietal region. Attempts were made to harness the autograft but it was rejected due to necrosis of the graft. On examination of the defect site, the patient was ambulatory, well oriented to space but showed mild neurological weakness in right hand. He also showed difficulty in remembering and recalling names of people but was able to follow instructions properly. Local Examination revealed a left FTP defect approximately 6.5" x 4.5" extending from supraorbital margin sparing zygoma just above external ear to mid cranium and upto mid-occipital region. (Fig. 1) Treatment plan was surgical decompressive cranioplasty and rehabilitation

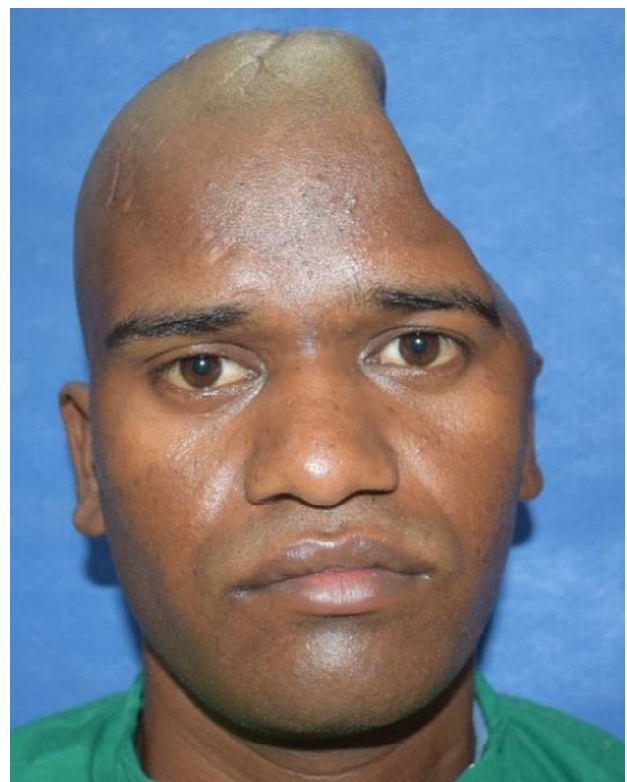


Fig. 1: Cranial Defect (Lt)

of residual cranial defect using Heat acrylized PMMA cranial implant.

After examination of defect site, the bony margin was marked by palpation and under supervision of neurosurgeon. A second marking was made about 0.5mm beyond the bony margin to allow overlap of implant over the bone to enhance placement of titanium mini screws during surgical phase. (Fig. 2) A full moulage of head was fabricated by making an impression using free flowing irreversible hydrocolloid to allow static recording of defect site in an uncompressed manner.

The impression was reinforced with plaster backing to support the impression. (Fig. 3) Once retrieved, the impression was poured using type III dental stone to fabricate stone model. (Fig. 4) A bevel was made to allow overlap of acrylic material over the healthy bone for securing the mini plates. The defect site on the model was blocked with type II gypsum product to get near normal contour as on unaffected side. Wax pattern was adapted over the model by using modelling wax and was finished. The finished wax pattern was tried onto the patient and was adjusted as per the contours of contralateral side. It was ensured that the pattern was

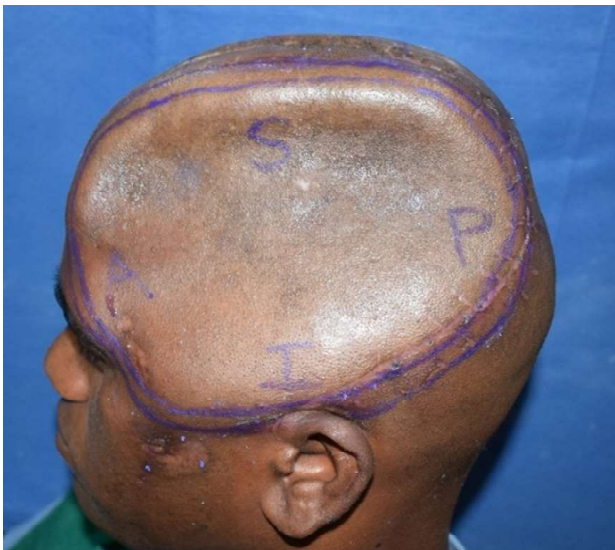


Fig. 2: Marking of bony margins and 0.5mm beyond the defect margin

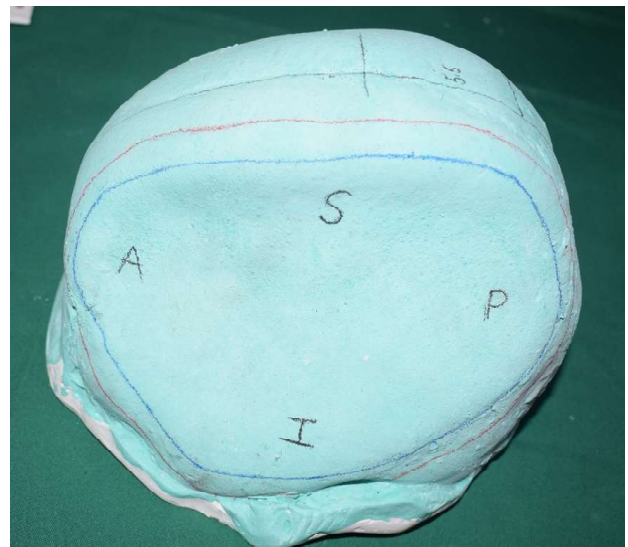


Fig. 4: Moulage

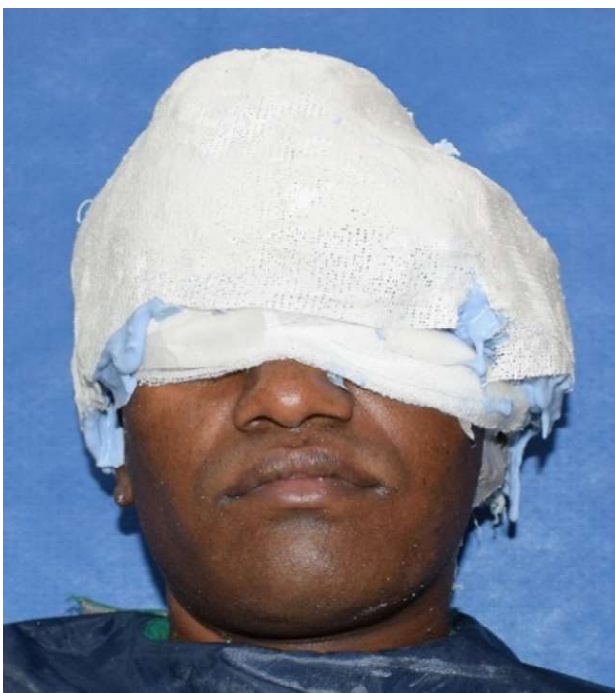

Fig. 3: Impression of Defect site

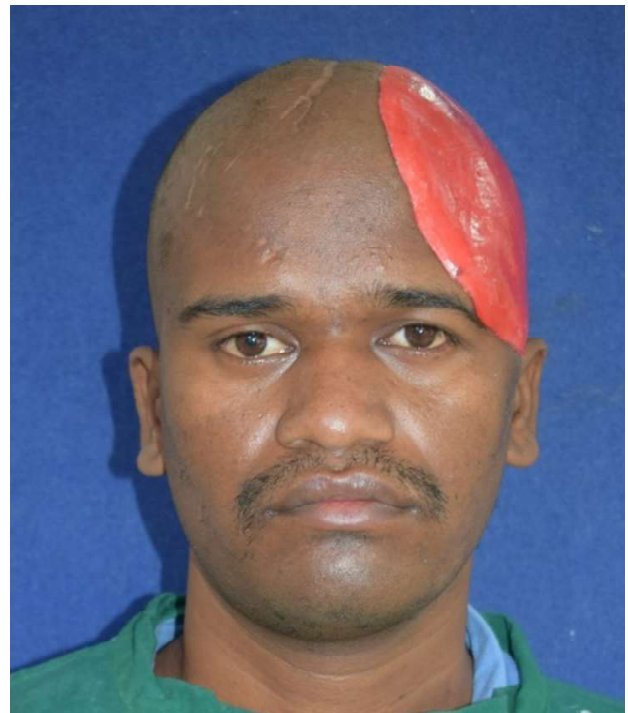


Fig. 5: Try-in Wax pattern

well adapted to the defect margin. (Fig. 5) The wax pattern was dewaxed and acrylized using heat cured PMMA. Polymer and monomer was mixed in recommended ratio of 3:1 and was packed in a flask. Long curing cycle was used to ensure minimum amount of residual monomer content. Finishing of prosthesis was done and the prosthesis was tried in. A customized 1.5cm graph sheet was used to ensure even perforations over the cranial implant using a no. 6 round bur. (Fig. 6)

In the surgical phase, a hemocoronal incision was made along the previous scar line. The duramater was carefully released taking special care not to cause perforation. Once carefully released. The cranial implant was placed and the margins overlapping healthy bone were secured using mini titanium screws. (Fig. 7) Post-surgical closure of defect site was achieved and a pressure dressing with a negative suction was placed. 07 days post-operative




Fig. 6: 1.5cm graph sheet for evenly spaced perforations

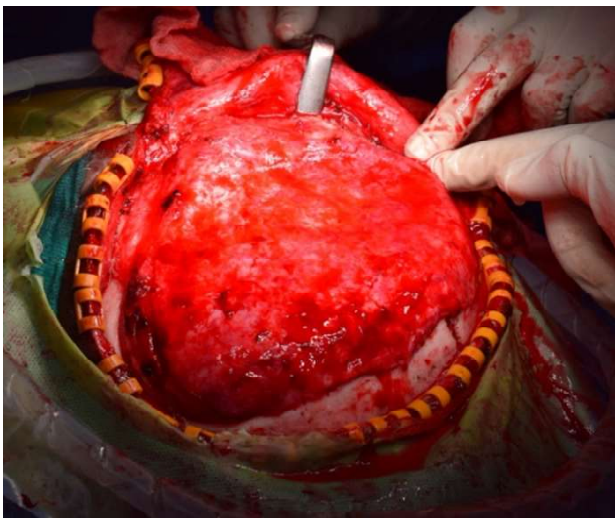


Fig. 7: Surgical procedure

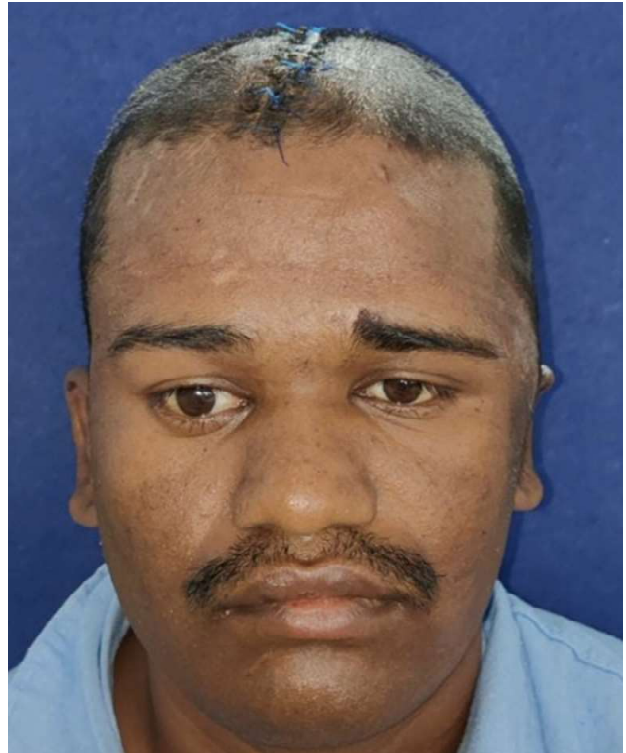
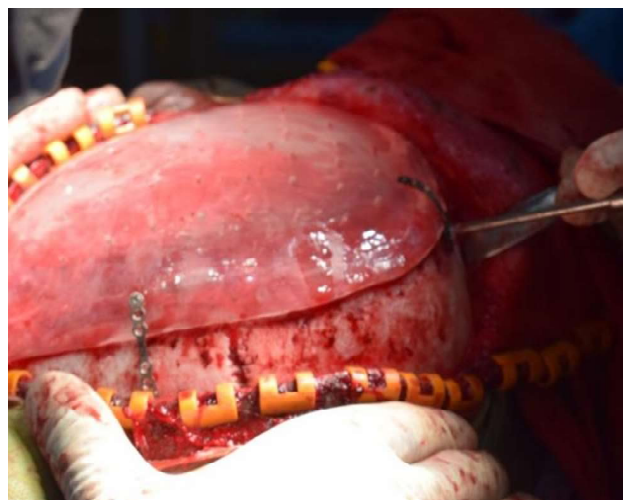

Fig. 8: Post-Operative View

showed well contoured implant. (Fig. 8) Patient was kept of follow-up at 02 weeks, 04 weeks, 02 months and 03 months. The healing was uneventful and his neuromuscular coordination showed remarkable improvement post-surgery.

DISCUSSION

The gold standard for cranial rehabilitation is considered to autogenous bone graft.⁷ However, due to risk of possible resorption, loss of contour, availability of limited graft material and donor site morbidity, alloplastic



materials are popularly used.

A meta-analysis indicated that complication rates of PMMA in cranioplasty showed no statistical difference from autologous bone grafts and titanium.⁸

Wael MA Ghani showed use of PMMA for rehabilitation of small and medium sized defects as a successful alternative and highlighted solution for common problems arising due to the same.⁹

The polymerization process of PMMA is initiated by reaction of benzoyl peroxide and N-dimethyl-p-toluidine. The reaction is highly exothermic i.e. generates heat while polymerization. Post-polymerization, PMMA releases about 3 to 5% of monomer residues and decreases to 1.2% eventually. No monomer is released after PMMA implantation, and no PMMA toxicity occurs after 48 and 78 months following surgical reconstruction¹⁰.

Amalgamation of recent technology using CAD/CAM and conventional materials like PMMA has also been attempted in which the defect was reconstructed using computer-aided design/computer-aided manufacturing (CAD/CAM) techniques. Acrylonitrile-butadiene-styrene model (ABS) of the patient's bony head were made using RP technique which used as a template for the intraoperative modeling of the PMMA cranioplasty.¹¹

CONCLUSION

PMMA has been successfully used as an economic material for rehabilitation of residual cranial defects. With advancements of newer materials, the choice of material and techniques has increased. However, clinical success with use of PMMA and titanium implants have made them as the most popular materials for rehabilitation even in today's era.

REFERENCES

1. **Martin JW, Ganz SD, King GE, Jacob RF, Kramer DC.** Cranial implant modification. *The Journal of prosthetic dentistry.* 1984 Sep 1;52(3):414-6.
2. **Harris DA, Fong AJ, Buchanan EP, Monson L, Khechoyan D, Lam S.** History of synthetic materials in alloplastic cranioplasty. *Neurosurgical focus.* 2014 Apr 1;36(4):E20.
3. **Aydin S, Kucukyuruk B, Abuzayed B, Aydin S, Sanus GZ.** Cranioplasty: review of materials and techniques. *Journal of neurosciences in rural practice.* 2011 Jul;2(2):162.
4. **Kharade P, Dholam K, Gorakh A.** A technique for fabrication of cranial prostheses using high-temperature vulcanizing silicone material. *The Journal of prosthetic dentistry.* 2017 Jul 1;118(1):113-5.
5. **Bogu VP, Kumar YR, Kumar KA.** 3D Printed, Customized Cranial Implant for Surgical Planning. *Journal of The Institution of Engineers (India): Series C.* 2018 Jun;99(3):255-9.
6. **Mishra SK, Chowdhary R.** Prosthetic Rehabilitation of Cranial Defects: An Overview. *Int J Prosthodont Restor Dent* 2019;9(2):33–34.
7. **Nandini Y, Venkatesh SB.** Prosthetic rehabilitation of cranial deformity in hyperostotic convexity meningioma. *Contemporary clinical dentistry.* 2018 Oct;9(4):674.
8. **Leao RD, Maior JR, Lemos CA, Vasconcelos BC, Montes MA, Pellizzer EP, Moraes SL.** Complications with PMMA compared with other materials used in cranioplasty: a systematic review and meta-analysis. *Brazilian oral research.* 2018;32.
9. **Abd El-Ghani WM.** Cranioplasty with polymethyl methacrylate implant: solutions of pitfalls. *Egyptian Journal of Neurosurgery.* 2018 Dec;33(1):1-4.
10. **Fernandes da Silva AL, Borba AM, Simão NR, Pedro FL, Borges AH, Miloro M.** Customized polymethyl methacrylate implants for the reconstruction of craniofacial osseous defects. *Case reports in surgery.* 2014 Jun 30;2014.
11. **Unterhofer C, Wiplinger C, Verius M, Recheis W, Thomé C, Ortler M.** Reconstruction of large cranial defects with poly-methyl-methacrylate (PMMA) using a rapid prototyping model and a new technique for intraoperative implant modeling. *Neurologia i neurochirurgia polska.* 2017 May 1;51(3):214-20.