

REVIEW ARTICLE

A COMPARATIVE EVALUATION OF PATIENT REPORTED PAIN PERCEPTION AND WOUND HEALING AFTER FRENECTOMY BY 980NM DIODE LASER AND CONVENTIONAL SCALPEL: A SYSTEMATIC REVIEW

Jaahnavi Lanka¹, Pratibha Gopalkrishna², Santhosh Kumar³

ABSTRACT

Abnormal frenal attachments pose problems like difficulty maintaining oral hygiene, gingival recession, and diastema. These conditions can predispose to periodontitis by causing attachment and bone loss. Hence, correcting abnormal frenal attachments becomes essential. The conventional scalpel method frenectomy is often associated with undesirable effects like bleeding, postoperative swelling, pain, and patient discomfort. As a result, alternative methods like electro-surgery and lasers have been used recently for frenectomy. Diode lasers are gaining popularity due to their suitability for soft tissues, ease of operation, and versatility. However, studies comparing diode lasers to conventional scalpel methods for frenectomy procedures are scarce and pose the research question, "Is the diode laser better than the conventional scalpel for frenectomy?" The present systematic review explores studies available on frenectomy using a 980nm diode laser compared with the conventional scalpel method. A literature search was carried out in databases like PubMed, Cochrane, Virtual Health Library, and Google Scholar from 2000 up to September 2021, using keywords, "Frenectomy," "Scalpel," and "980nm diode laser." A total of 363 articles were screened for suitability using the PRISMA

guidelines and PICO criteria. The search strategy is illustrated in a flow chart. The present systematic review has been registered with PROSPERO.

Keywords: Frenectomy, Laser, Scalpel, 980nm diode, Wound healing.

INTRODUCTION

High frenal attachments are mucogingival deformities^{1,2} that pose problems like difficulty maintaining oral hygiene, gingival recession,³ and diastema.⁴ These conditions can predispose to periodontitis by causing attachment and bone loss³⁻⁵. Apart from these conditions, high frenal attachments can also hamper denture stability in edentulous ridges.⁶

Hence, correcting the abnormal frenal attachments becomes essential, which is done by a minor surgical procedure called frenectomy. The conventional scalpel methods are associated with pain, bleeding, postoperative swelling, and discomfort.⁷⁻¹⁷ To overcome these shortcomings and increase patient compliance, alternative methods like electro-surgery¹³⁻¹⁷ and lasers⁷⁻¹² for frenectomy have been studied. Diode lasers are gaining popularity due to their suitability for soft tissues, portability, cost-effectiveness, ease of operation, simple setup, and versatility.

Studies comparing diode lasers to conventional scalpel methods for frenectomy appear scarce, posing the research question: "Is the 980nm diode laser better than the conventional scalpel for frenectomy?"

The present systematic review aims to answer the research question mentioned above.

MATERIALS AND METHODS

A literature search was carried out in databases like PubMed, Cochrane, Virtual Health Library, and Google Scholar from 2000 up to September 2021, using keywords, "Frenectomy," "Scalpel," and "980nm diode laser." A total of 363 articles were screened for suitability using the PRISMA guidelines¹⁸ and PICO¹⁹ criteria

-
1. MDS (Ph.D.)
Clinic Head, Paradise, Clove Dental Hyderabad.
 2. MDS
Professor, Department of Periodontology,
Manipal College of Dental Sciences, Manipal, Manipal
Academy of Higher Education (MAHE), Manipal,
Karnataka, India - 576104
Email : pratibha.pk@manipal.edu
 3. MDS,
Associate Professor, Manipal College of Dental Sciences,
Manipal, Manipal Academy of Higher
Education(MAHE), Manipal, Karnataka,
India - 576104
Email: santhosh.kumar@manipal.edu

Corresponding Author

Dr. Jaahnavi Lanka, MDS (PhD)
Clinic Head, Paradise, Clove Dental Hyderabad.

described below.

Patients: Patients with high frenal attachments

Intervention: frenectomy

Comparison: laser compared to scalpel

Outcome measures: pain, wound healing, the width of keratinized gingiva, reattachment of the frenum, and periodontal clinical parameters.

The systematic review has been registered with PROSPERO: CRD42021282926.

INCLUSION CRITERIA

1. Randomised controlled trials from 2000 to 2021
2. Studies with low risk and medium risk of bias
3. Studies that have used 980nm diode laser only
4. Studies that compared laser with the conventional scalpel method

EXCLUSION CRITERIA

1. case reports and series
2. studies with a high risk of bias
3. studies that used other types of lasers

SCREENING

Initially, titles and abstracts were screened, and duplicates were excluded. Two independent examiners, EE1 and EE2, assessed the eligibility of the included studies. In cases of disagreement, judgment from a third examiner was taken. Eligible studies went through a full-text reading, and reference lists of eligible articles were screened for suitable studies to be included.

QUALITY ASSESSMENT

The quality of studies was assessed by the criteria given by Oxford Centre for Evidence-based medicine.²⁰

BIAS ASSESSMENT OF INCLUDED STUDIES

‘Cochrane recommendations to assess bias²¹ were used to categorize studies into low risk, medium risk, and unclear risk of bias, as described in table 1. The search strategy is illustrated in figure 1.

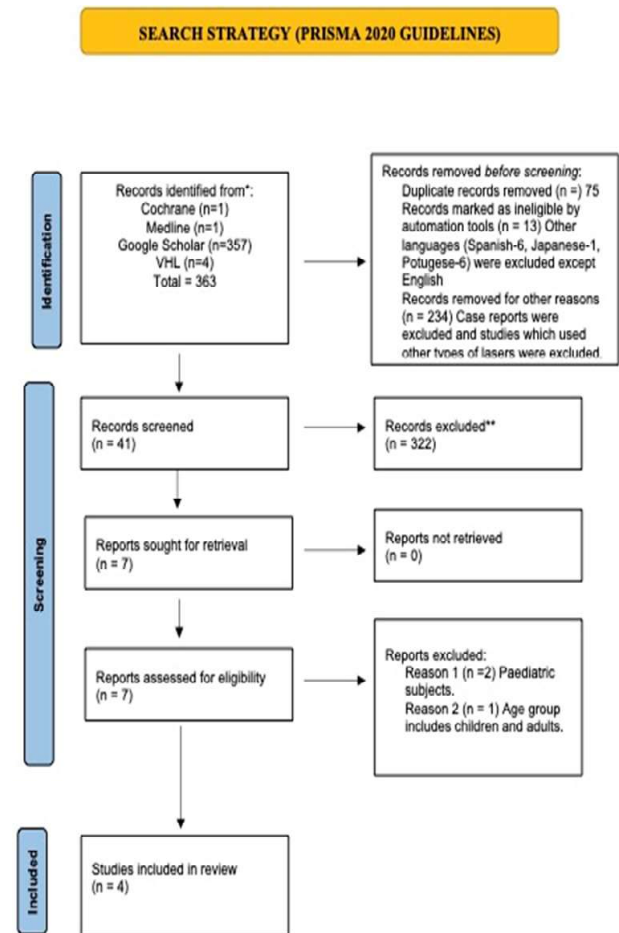


Fig. 1: Search Strategy

Table 1: Risk of bias assessment as per Cochrane recommendations

Author/Type of study	Random sequence generation	Allocation concealment	Blinding of participants and personnel	Blinding of outcome assessment	Incomplete outcome data	Selective reporting	Other bias
Thakur K et al.[8] 2020	Yes	Unclear	NA*	NA*	No	No	No
Singh P et al.[9] 2019	Yes	Unclear	NA*	NA*	No	No	No
Uraz A et al.[10] 2018	Yes	Unclear	NA*	NA*	No	No	No
Patel RM et al. [11] 2015	Yes	Unclear	NA*	NA*	No	No	No

* Not Applicable

RESULTS OF SYSTEMATIC REVIEW

The data from the included studies have been extracted and tabulated in **table 2**. Only four studies⁸⁻¹¹ met the inclusion criteria after excluding studies with a high risk of bias. Studies that used other types of lasers were excluded. All four studies were carried out in dental universities. 86 patients in the included studies underwent frenectomy either by a 980nm diode laser or scalpel method. The studies were restricted to the maxillary frenum only.

The outcome measures common for all four studies were,

- i. patient-reported pain perception on a visual analog scale (VAS)
- ii. bleeding & swelling
- iii. wound healing

One study [10] included periodontal clinical parameters – plaque index (PI), gingival index (GI), bleeding on probing (BOP), pocket probing depth (PPD), the width of keratinized tissue (KGW), attached gingiva (AGW), and attached gingival thickness (AGT), which had a follow up of six months. The other studies had a follow-up of three months¹¹ and thirty days^{8,9}, respectively.

Thakur K *et al.*⁸ included ten patients with abnormal maxillary frenal attachments randomly assigned to two groups. Group A subjects underwent frenectomy by a conventional scalpel method, and Group B subjects underwent frenectomy by a 980nm diode laser (Zolar Tech technology). The frenectomy procedure followed the method described by Archer²² and Kruger.²³

The power settings in the laser group were adjusted at 2W continuous wave mode, and a 400um fiber optic tip was used. Remnants of charred tissue were removed using sterile gauze dipped in saline. Instructions regarding laser safety and the use of protective eyewear by the patient and the operators were also given. The outcome measures assessed were bleeding during the procedure, and on the first and second postoperative days, on a four-point scale, from 1 to 4. Patient-reported pain perceptions were assessed on postoperative days 1 and 2 on a 10mm VAS scale. The swelling was evaluated on a three-point scale from 0 to 2 on the first, third, and seventh postoperative days. Wound healing assessment was made by clinical examination on a three-point scale at one month. Wound healing at seven days or fourteen days was not assessed.

Table 2: Analysis of data from the included studies

Author & Year	Study Type & Place	No of Patients & Age Group	Duration	Treatment modality	Type of frenum & Indication	Outcome parameters	Results
Thakur K <i>et al.</i> [8] 2020	RCT; Aurangabad, India.	10 Patients 18-30years	1 month	1. Conventional frenectomy operation (Group: A) 2. Diode laser-assisted frenectomy (Group: B)	Abnormal labial frenula of maxillary region	1. Bleeding (during surgery, 1st-day post op, 2nd-day post-op) 2. Pain (postoperatively 1st & 2nd day) 3. Swelling (postoperatively 1st, 3rd, & 7th day) 4. Wound healing (1-month post-surgery)	Bleeding and pain were found to be significantly less in the laser group. While swelling in the laser group was significantly less on the 1 st and 7 th postoperative days, no significant differences were found between the laser and scalpel groups. Wound healing evaluated at one month showed no significant differences between the groups.
Singh P <i>et al.</i> [9] 2019	RCT; Patna, India	20 Patients 18-45 years	30 days	1. Conventional Scalpel 1. 980 nm Diode laser	Maxillary labial frenum	1. VAS [†] - discomfort during the speech, bleeding severity, swelling, redness 2. Wound healing	The diode laser group showed statistically significant benefits in clinical and healing outcomes compared to the scalpel group.
Uraz A <i>et al.</i> [10] 2018	RCT; Turkey	36 Patients 14-51 years	Six months	1. Conventional Scalpel 2. 980 nm Diode laser	Papillary and Papillary penetrating maxillary frenal attachments & labial frenectomies are done as a part of orthodontic, prosthodontic, or periodontal treatment.	1. VAS [†] 2. KGW [‡] 3. AGW [§] 4. AGT measured at baseline, 1, 3, and 6 months 5. PI [¶] , GI ^{**} , PPD ^{††} , CAL ^{‡‡} and BOP ^{§§}	KGW [‡] , AGW [§] and AGT after surgery showed a statistically significant increase in both groups; the Diode laser group showed lesser pain scores than the scalpel group.
Patel RM <i>et al.</i> [11] 2015	RCT; Maharashtra India	20 Patients 16-40 years	Three months	1. Conventional Scalpel 2. 980 nm Diode laser	Papillary or papillary penetrating frenal attachments in the maxillary anterior region were selected.	1. Pain, inflammation, swelling, the difficulty of the procedure 1. Wound healing	The diode laser group showed lower VAS [†] scores, and fewer analgesics were consumed compared to the scalpel group. The scalpel group showed better-wound healing, which is statistically significant on the 7th day and one month when compared to the laser group. At three months, wound healing did significantly differ between the groups.

1 Randomized Clinical Trial
 † Visual Analogue Scale
 ‡ Keratinized Gingiva Width
 § Attached Gingiva Width
 || Attached Gingiva Thickness
 ¶ Plaque Index

** Gingival Index
 †† Probing Pocket Depth
 ‡‡ Clinical Attachment Loss
 §§ Bleeding on Probing

The analysis of results indicated that significantly lower scores were seen for bleeding during the procedure and on the first and second postoperative days in the laser group compared to the scalpel group. Significantly lower scores were also seen for pain perception in the laser group. Postoperative swelling scored higher in the scalpel group compared to the laser group on the first and third days. On the seventh day, there were no significant differences in postoperative swelling between the groups. Assessment of wound healing at one month showed no statistically significant difference between the groups. Their observations were consistent with the findings of Haytac *et al.*⁷

Singh P *et al.*¹⁰ studied twenty subjects with high frenal attachments in the maxilla. A coin toss was used to assign the participants to either a 980nm diode laser group or a conventional scalpel frenectomy. A 400µm fiber tip was used in the laser group with power settings at 1.5 W in contact mode, and the tip was moved with a paintbrush technique from the base to the apex of the frenum. The laser group did not require sutures or a periodontal pack. The outcome measures were pain and discomfort during speech on a 100mm VAS scale; bleeding was assessed from 0-3; redness on a five-point scale; and inflammation as present or absent on the first, seventh, and thirtieth day after the procedure.

Wound healing was assessed at seven and thirty days postoperatively, scoring as 1: complete epithelialization, 2: incomplete epithelialization, 3: ulcer, and 4: tissue defect or necrosis. The name and procedure of wound healing evaluation were not mentioned.

The VAS scores for pain and discomfort during the speech were significantly lesser for the laser group as compared to the conventional group on days 1 and 7, and no pain was noted at thirty days in both groups. The laser-treated group showed faster wound healing than the conventional surgery group. Redness was found to be significantly higher in the conventional group.

Uraz *et al.*¹⁰ performed labial frenectomies in a prospective randomized controlled trial on 36 patients with maxillary frenal attachments extending up to the interdental papilla. The study aimed to evaluate frenum reattachment, keratinized tissue gain, patient-reported pain perceptions, and functional complications following the frenectomy procedure. The method of randomization of study participants was not mentioned. Although forty patients participated at the beginning of the study, four could not complete it. The conventional group included 16 patients, while the diode laser group included 20 patients. A sample size of fifteen patients per group was calculated, with 80% power.

It may be noted that eight patients in the laser group required anesthesia, which could have affected the pain perception during the procedure. Laser settings were adjusted at 2.8 W, continuous wave mode with an air-cooling handpiece. The periosteal adhesion was removed using the laser. Tissue charring was removed with saline, and no sutures were placed in the laser group.

No statistically significant differences were observed in the periodontal parameters assessed between the two groups. Visual analog scale (VAS) scores for pain, swelling, or redness in the groups were not significantly different, although the laser group showed lesser VAS scores for pain. The swelling scores were higher on the first day in the laser group than in the conventional group. On the fifth day, the swelling scores were reduced in the laser group. The intragroup analysis of VAS pain scores in the laser group showed decreasing pain levels from the first to the seventh day. In contrast, pain levels remained consistent in the conventional group throughout the duration.

The VAS scores for discomfort in speaking were higher in the conventional group than in the laser group, although the results were not statistically significant. The conventional group had higher VAS scores for 'discomfort due to chewing' compared to laser on the first and second postoperative days.

The study claimed to be the first to assess soft tissue parameters like keratinized gingiva width (KGW), attached gingiva width (AGW), and attached gingiva thickness (AGT), which showed statistically significant gains in both groups. Only a few frenula recurrences were noted at the third-month review. However, the number of recurrences and the group in which these recurrences were reported have not been discussed. Further, no reasons were attributed to the recurrence. No significant differences were noted in pain perception between the two groups. About 40% of patients in the laser group did not require anesthesia. Therefore, the use of anesthesia for pain management in the rest of the patients within the laser group could have influenced pain perceptions. The authors concluded that diode lasers were a safe and comfortable alternative for labial frenectomies.

Patel *et al.* 2015¹¹ conducted a randomized controlled clinical trial involving twenty patients with papillary and papillary penetrating frenal attachments in the maxillary arch. Parameters assessed were postoperative pain, inflammation, swelling, the difficulty of the procedure, and wound healing at one week, one month, and three months. A single examiner carried out all the procedures. The conventional technique involved the excision of the frenum by the classical technique described by Archer²²

and Kruger.²³ Frenal excision was carried out using a 980nm diode laser (Photon Plus; Zolar Tech Technology and MFG Co. Inc., Canada) at a power setting of 10 W, with the fiber tip used in a contact mode. While all the patients in the conventional group required sutures and a periodontal pack, some patients in the laser group also were given sutures and a periodontal pack. The earlier studies did not mention using either sutures/pack for the laser group.

Pain during the procedure, and postoperative pain perception on day one and day seven were scored on a 10cm VAS scale. The operator on a four-point scale scored the ease of operation. Swelling and wound healing were assessed at three-time points, i.e., one week, one month, and three months postoperatively. The results showed that the mean VAS scores for pain on the first and seventh days were lower for the laser group than the conventional group. The analgesic consumption was also noted, which showed higher analgesic consumption in the conventional group. The bleeding scores in the conventional group were significantly higher than the laser group (assessed on a four-point scale previously used by Ishii *et al.*²³)

The wound healing assessment at seven days and one month indicated that the laser group had significantly delayed wound healing compared to the conventional group. At three months, the differences in wound healing seemed to diminish between the groups. These results were consistent with previous studies by Haytac *et al.*⁶ and Butchibabu *et al.*¹¹

DISCUSSION

Correction of aberrant frenal attachments is a crucial aspect of mucogingival surgery. Scalpel methods have conventionally been the first treatment of choice for frenectomy. However, minimally invasive surgical techniques are increasingly gaining importance as alternative treatment modalities. Lasers now offer an option as either adjuncts or stand-alone treatment modalities. The present systematic review compared the efficacy of the frenectomy procedure performed with a 980nm diode laser to the conventional scalpel method.

Among the four studies in the present review, outcome measures commonly included VAS scores for pain, discomfort, swelling, and difficulty in chewing following the procedure. Patel *et al.*¹¹ found that the pain scores of subjects who underwent laser procedures were significantly lower than conventional scalpel methods. It was the only study to evaluate pain during the procedure, with the laser-operated group showing less pain and reduced postoperative pain. Their study¹¹ further

analyzed ease of operation on a four-point scale. Uraz *et al.*¹⁰ noted swelling in the laser group on the first post-operative day only, while swelling in the conventional group was reduced by the fifth postoperative day. VAS scores for pain, swelling, and difficulty chewing and speaking indicated that laser-assisted frenectomy presents with less pain and functional difficulty. Pain perception is generally subjective in nature and differs from patient to patient depending on factors that influence their pain thresholds, like stress and the psychological status of patients.

Wound healing presented contradictory results, with some studies⁸⁻¹⁰ showing better healing with lasers, while others^{11, 26} showing faster healing with conventional methods. Further long-term clinical trials using appropriate wound healing indices are warranted.

To enhance healing followed by laser frenectomy, Cankaya *et al.*²⁵ used hyaluronic acid gel on the wound surface immediately after the procedure at 3, 7, and 14 days, while a control group treated with laser frenectomy received no such application. Their results showed that hyaluronic acid enhanced wound healing and patient satisfaction by decreasing the wound surface area and providing a wound-dressing effect. The observations of this study recommended the use of adjuncts to wound healing in laser-assisted frenectomies.

Overall, the advantages of diode lasers, such as less perioperative and postoperative pain, bloodless field, enhanced visibility, accessibility, and precision incision margins, outweigh the demerits. Diode laser-assisted frenectomy appears to be a time-saving and easy-to-perform alternative for clinicians, with greater patient acceptance.

CONCLUSION

The following observations have been made from the results of the present systematic review,

- i. Lasers can be used as effective, painless alternatives to conventional scalpel methods for frenectomy.
- ii. Laser wound healing is delayed in some studies, while others present contradictory results. Hence, this aspect needs further evaluation through randomized clinical trials to arrive at an evidence-based conclusion.
- iii. The benefits of using lasers for frenectomy outweigh the demerits, confirming the 980nm diode laser to be an effective and minimally invasive alternative to the conventional scalpel method, with improved patient compliance, reduced chair-side time, and ease of operation.

ETHICS STATEMENT

The systematic review followed PRISMA [17] guidelines.

FUNDING INFORMATION

No funds were utilized to conduct this systematic review.

CONFLICTS OF INTEREST

The authors declare that they have no conflicts of interest.

ACKNOWLEDGMENTS

We would like to acknowledge the assistance provided by EE1 and EE2 as internal examiners.

DATA AVAILABILITY STATEMENT

All the data, including tables and figures, is included in the manuscript.

REFERENCES

1. **Oesterle LJ, Shellhart WC.** Maxillary Midline Diastemas: A Look at The Causes. *The Journal of the American Dental Association.* 1999;130(1):85-94.
2. **Cortellini P, Bissada NF.** Mucogingival conditions in the natural dentition: Narrative review, case definitions, and diagnostic considerations. *Journal of Periodontology.* 2018;89: S204-S213.
3. **Jati AS, Furquim LZ, Consolaro A.** Gingival recession: its causes and types, and the importance of orthodontic treatment. *Dental Press Journal of Orthodontics.* 2016;21(3):18-29.
4. **Gkantidis N, Kolokitha O-E, Topouzelis N.** Management of maxillary midline diastema with emphasis on etiology. *Journal of Clinical Paediatric Dentistry.* 2008;32(4):265-272.
5. **Mirko P, Miroslav S, Lubor M.** Significance of the Labial Frenum Attachment in Periodontal Disease in Man. Part 1. Classification and Epidemiology of the Labial Frenum Attachment. *Journal of Periodontology.* 1974;45(12):891-894.
6. **Priyanka M, Sruthi R, Ramakrishnan T, Emmadi P, Ambalavanan N.** An overview of frenal attachments. *Journal of Indian society of Periodontology.* 2013 Jan;17(1):12.
7. **Haytac MC, Ozelik O.** Evaluation of Patient Perceptions After Frenectomy Operations: A Comparison of Carbon Dioxide Laser and Scalpel Techniques. *Journal of Periodontology.* 2006;77(11):1815-1819.
8. **Indurkar MS, Thakur K.** Comparison of Labial Frenectomy by Conventional Surgical Technique versus Diode Laser. *International Journal of Medical Science and Current Research.* 2020 Jul;3(4):153.
9. **P, Nath S.** Diode laser versus conventional technique for frenectomy-A randomized controlled clinical trial. *Int. J. Appl. Dent. Sci.* 2019; 5(2): 04-07 2019.
10. **Uraz A, Çetiner FD, Cula S, Guler B, Oztoprak S.** Patient perceptions and clinical efficacy of labial frenectomies using diode laser versus conventional techniques. *Journal of Stomatology, Oral and Maxillofacial Surgery.* 2018;119(3):182-186.
11. **Patel R, Varma S, Suragimath G, Abbayya K, Zope S, Kale V.** Comparison of labial frenectomy procedure with conventional surgical technique and diode laser. *Journal of Dental Lasers.* 2015;9(2):94.
12. **Butchibabu K, Koppolu P, Mishra A, Pandey R, Swapna LA, Uppada UK.** Evaluation of patient perceptions after labial frenectomy procedure: A comparison of diode laser and scalpel techniques. *European Journal of General Dentistry.* 2014;3(02):129-133.
13. **Shah S, Rathwa V, Shah M, Dave D.** Frenectomy Using Electrocautery: A Case Series. *Advances In Human Biology.* 2013 Aug 30;3(2):26-30.
14. **Babaji P, Singh V, Chaurasia VR, Jawale MR.** Electro surgery in dentistry: Report of cases. *J Pediatr Dent [Internet].* 2014;1(2).
15. **Bhullar A, Verma S, Bhullar SK.** A comparison of frenectomy using Electrocautery and Scalpel Techniques. *International Journal of Research in Health and Allied Sciences.* 2018;4(4):42-5.
16. **Dias C, Kamat SV.** Frenectomy: Management By Electrosurgery-A Report Of Two Cases. *Medico Research Chronicles.* 2020 Nov 21;7(6):312-21.
17. **Mazzoni A, Navarro RS, Fernandes KP, Mesquita-Ferrari RA, Horliana AC, Silva T, Santos EM, Sobral AP, Júnior AB, Nammour S, Motta LJ.** Comparison of the Effects of High-Power Diode Laser and Electrocautery for Lingual Frenectomy in Infants: A Blinded Randomized Controlled Clinical Trial. *Journal of Clinical Medicine.* 2022 Jun 30;11(13):3783.
18. **Moher D, Liberati A, Tetzlaff J, Altman DG.** Preferred reporting items of systematic review and meta-analyses: the PRISMA statement. *Deutsche Medizinische Wochenschrift.* 2011 Apr 5;136(15).
19. **Miller SA, Forrest JL.** Enhancing your practice through evidence-based decision making: PICO, learning how to ask good questions. *Journal of Evidence-Based Dental Practice.* 2001 Oct 1;1(2):136-41.
20. **Shaneyfelt T.** Resource review on How to Read a Paper - The Basics of Evidence-Based Medicine. Fourth edition. Oxford: Wiley-Blackwell 2010. *Evidence-Based Medicine.* 2011;16(1):6-6.
21. **Lundh A, Gøtzsche PC.** Recommendations by Cochrane Review Groups for assessment of the risk of bias in studies. *BMC medical research methodology.* 2008 Dec;8(1):1-9.
22. **A Manual of Oral Surgery: A Step-by-Step Atlas of Operative Techniques.** *Journal of the American Medical Association.* 1956;162(7):693.
23. **Kruger HEC.** Surgical management of a median mandibular facial cleft (Tessier 30). *International Journal of Oral and Maxillofacial Surgery.* 2011;40(10):1205-1206.

24. **Ishii S, Aoki A, Kawashima Y, Watanabe H, Ishikawa I.** Application of an Er: YAG laser to remove gingival melanin hyperpigmentation: Treatment procedure and clinical evaluation. *J Jpn Soc Laser Dent.* 2002;13(2):89-96.
25. **Çankaya ZT, Gürbüz S, Bakırarar B, Ünsal B, Kurti° B.** Evaluation of the effect of the application of hyaluronic acid following laser-assisted frenectomy: an examiner-blind, randomized, controlled clinical study. *Quintessence International.* 2020 Mar 1;51(3):188.
26. **Glazer H.** Soft tissue diode laser. *Oral Health* 2010;100(7):22.
27. **Aoki A, Mizutani K, Schwarz F, Sculean A, Yukna RA, Takasaki AA, Romanos GE, Taniguchi Y, Sasaki KM, Zeredo JL, Koshy G.** Periodontal and peri implant wound healing following laser therapy. *Periodontology* 2000. 2015 Jun;68(1):217-69.
28. **Sewerin I.** Prevalence of Variations and Anomalies of the Upper Labial Frenum. *Acta Odontologica Scandinavica.* 1971;29(4):487-496.