

## CASE REPORT

## APEXIFICATION IN NON-VITAL TOOTH WITH OPEN APEX: A REPORT OF TWO CASES

Sharad Sharma <sup>1</sup>

### ABSTRACT

*Apexification is a method of inducing apical closure for non-vital immature permanent teeth. During this treatment a mineralized barrier is induced [with long term calcium hydroxide (CH) treatment]; or artificially created [with mineral trioxide aggregate (MTA) plug]. Method : Two patients presented for evaluation of central incisor with discoloration with mild swelling and a nontraceable sinus tract. Both have a history of trauma. After intraoral examination and radiographic assessment a diagnosis of pulp necrosis with open apex was made. At the initial visit access cavity preparation and biomechanical preparation was done and calcium hydroxide dressing was placed. In the next appointment MTA plug was made and obturation was done after 72 hours and the tooth was build up with composites and a porcelain fused to metal crown was delivered. MTA is used for creating an apical plug, the functional goal of this procedure is to provide a hard tissue barrier that will provide an apical stop for effective obturation of the canal allowing the patient to maintain the tooth. Conclusion: MTA can be used effectively for creating a hard calcific barrier in cases of open apex. MTA also has low cytotoxic and superior biocompatibility as compared to calcium hydroxide used before.*

**Keywords :** *Apexification, MTA, Open apex.*

### INTRODUCTION

Root development is through the continuous deposition of dentin and cementum by stimulation and differentiation of Hertwig's Epithelial Root Sheath (HERS) and surrounding progenitor cells. Interference in this development by trauma or infection can lead to interruption and arrest of root development which presents with thin and fragile dentinal wall and an absence

of natural apical constriction that can create challenging clinical situations. The apical anatomy in these teeth is characterized by greater width at the apical portion compared to the cervical and the absence of apical constriction that challenge the clinician with difficulty in determining and staying within the working length <sup>1,2</sup>. The very thin root dentin walls render the tooth susceptible to fracture. In such cases, it is necessary to induce the closure of the apical foramen with mineralized tissue or to create an artificial apical barrier to allow for condensation of the root filling material and promote an apical seal <sup>3</sup>. Apexification is a method of inducing the formation of a calcified barrier in a root with an open apex or the continued apical development of an incompletely formed root in teeth with necrotic pulp.<sup>4</sup> This procedure consists of removal of inflamed or necrotic pulp from the root canal, and disinfection of the canal to create an environment favorable for closure of the apex. The functional goal of this procedure is to provide a hard tissue barrier that will provide an apical stop for effective obturation of the canal allowing the patient to maintain the tooth. Mineral trioxide aggregate (MTA) has become a common alternative to traditional apexification treatment with calcium hydroxide.<sup>5,6</sup> Current literature supports its efficacy in several procedures including apexification or as a root end filling material for root end closure of non-vital teeth with open apices.<sup>7</sup> MTA is biocompatible, bactericidal, and able to set up in the presence of blood. It exhibits good sealing properties and favors the regeneration of periradicular tissues including bone and cementum.<sup>8</sup>

### CASE REPORT

#### CASE 1

A 25-year-old male patient reported to the clinic with a chief complaint of discolored teeth in the upper front region of the mouth with a history of trauma 11 years ago. Clinical examination revealed discoloration. Tooth responded normally to percussion, palpation and had normal periodontal probing. Radiographic examination demonstrated the presence of open apex and bone loss (Fig 1).

Pulp vitality tests, including the cold test and an electric pulp testing elicited a negative response, which

---

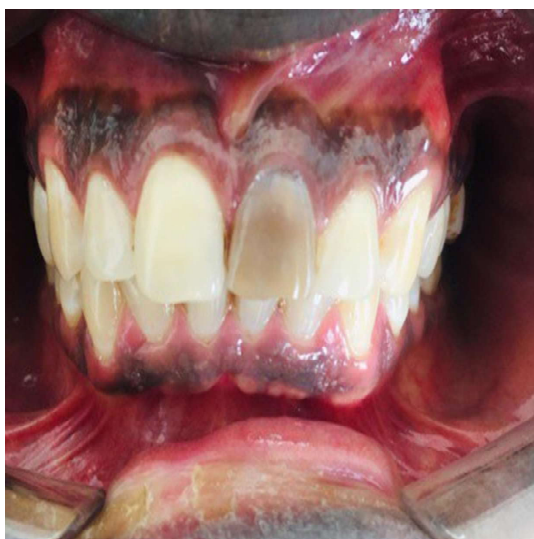1. Conservative Dentistry And Endodontics, Consultant, Clove Dental

#### **Corresponding Author**

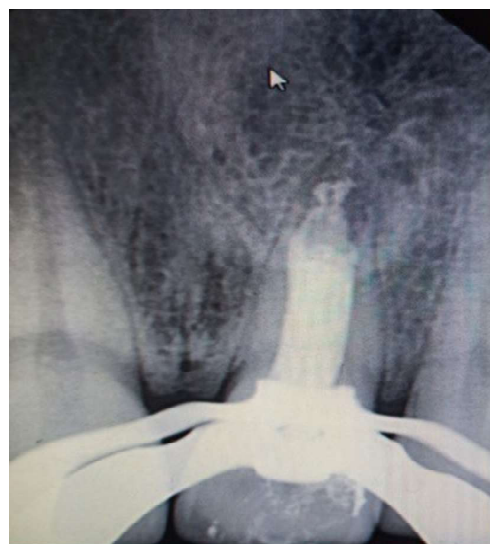**Dr Sharad Sharma**

(M.D.S) Conservative Dentistry And Endodontics, Consultant, Clove Dental

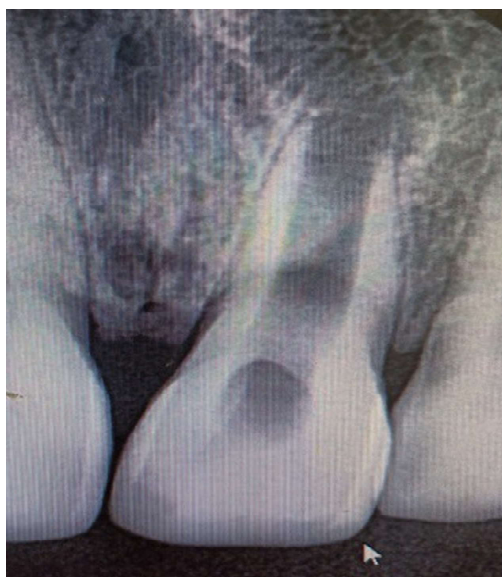**Email:** sharad.sharma@clovedental.in



**Fig. 1**



**Fig. 3: Calcium Hydroxide Placed**



**Fig. 2: Preoperative Radiograph**

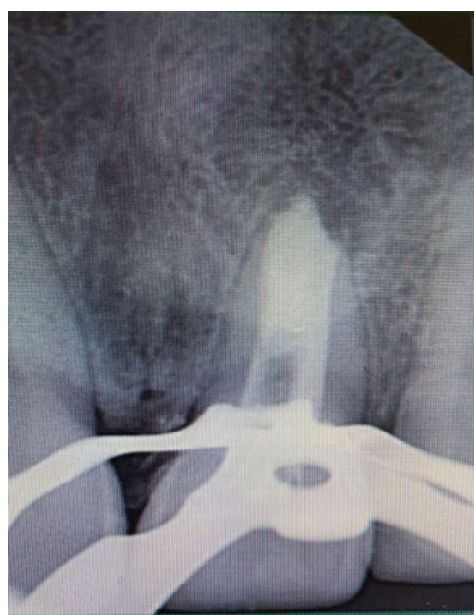and the canal was dried with paper points. MTA (Dentsply, Tulsa Dental, and Johnson City, USA) was mixed according to the manufacturer's instructions and carried to the canal with an amalgam carrier. Apical plug of 6 mm of thick paste of MTA was placed and confirmed radiographically (Fig 3). A sterile cotton pellet moistened with sterile water was placed over the canal orifice and the access cavity was sealed with Cavit (3M ESPE, Seefeld, Germany).

After 72 hours, the hard set of MTA was confirmed and the remainder of the root canal was obturated with cold lateral compaction and zinc oxide eugenol sealer (Fig 4). followed with post endo restoration with composite.

was suggestive of pulp necrosis. The available treatment options were discussed with the patient and root canal therapy using MTA as an apical barrier was selected.

The tooth was isolated under rubber dam and access cavity prepared. Working length was established by radiograph. The canal was gently debrided with large H-files (Dentsply Maillefer, Ballaigues, Switzerland) by doing circumferential filling and copious amounts of 5% sodium hypochlorite. Calcium hydroxide intra canal medicament was placed for one week to disinfect the root canal (fig. 3)

At the second appointment, calcium hydroxide was flushed with 5% sodium hypochlorite and rinsed with saline. Final irrigation was done with 2% chlorhexidine



**Fig. 4: MTA Apical Plug**

**CASE 2**

A 16-year-old male patient reported to the clinic with a chief complaint of fractured upper anterior tooth with a history of trauma 9 years ago. Clinical examination revealed Ellis class II fracture in maxillary right central incisor and discoloration. Tooth responded normally to percussion, palpation and had normal periodontal probing. Radiographic examination demonstrated the presence of open apex and periapical radiolucency. The tooth did not respond to the pulp vitality tests.

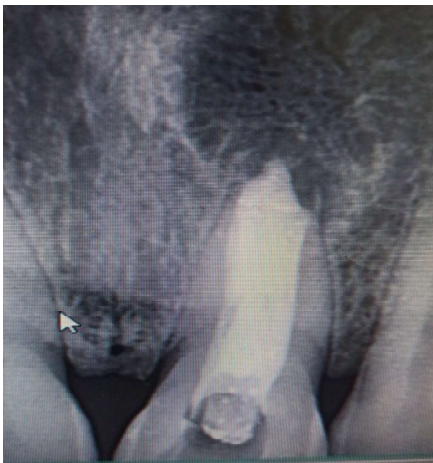The final diagnosis is pulp necrosis with chronic apical periodontitis. The available treatment options were discussed with the patient and root canal therapy using MTA as an apical barrier was selected.

The tooth was isolated under rubber dam and access cavity prepared. Working length was established by radiograph. The canal was gently debrided with large H-files (Dentsply Maillefer, Ballaigues, Switzerland) by doing circumferential filling and copious amounts of

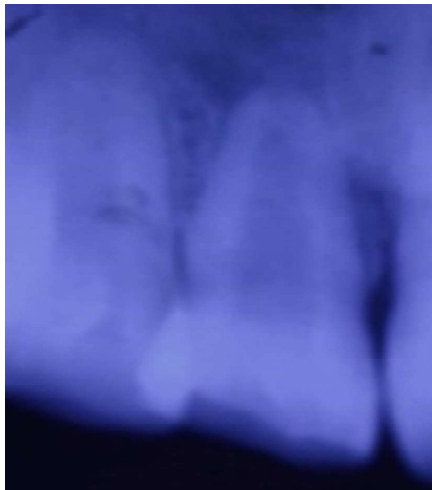
5% sodium hypochlorite. Calcium hydroxide intra canal medicament was placed for one week to disinfect the root canal.

At the second appointment, calcium hydroxide was flushed with 5% sodium hypochlorite and rinsed with saline. Final irrigation was done with 2% chlorhexidine and the canal was dried with paper points. MTA (Dentsply, Tulsa Dental, and Johnson City, USA) was mixed according to the manufacturer's instructions and carried to the canal with an amalgam carrier. Apical plug of 6 mm of thick paste of MTA was placed and confirmed radiographically (Fig 3). A sterile cotton pellet moistened with sterile water was placed over the canal orifice and the access cavity was sealed with Cavit (3M ESPE, Seefeld, Germany)

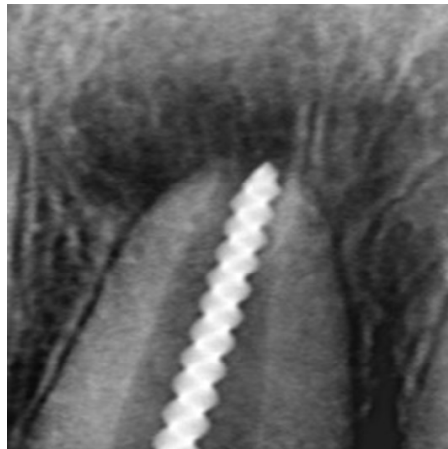
After 72 hours, the hard set of MTA was confirmed and the remainder of the root canal was obturated with cold lateral compaction and zinc oxide eugenol sealer (Fig 4). followed with post endo restoration with composite.



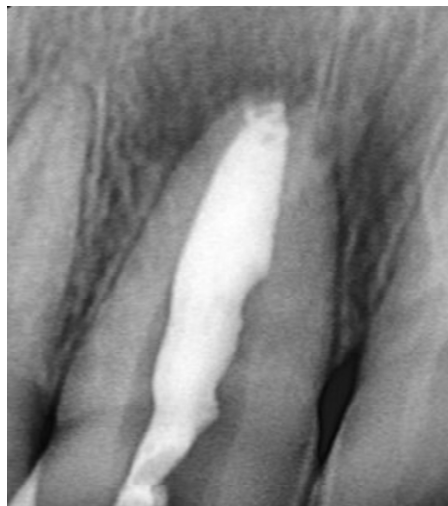**Fig. 5: Post Operative Radiograph**



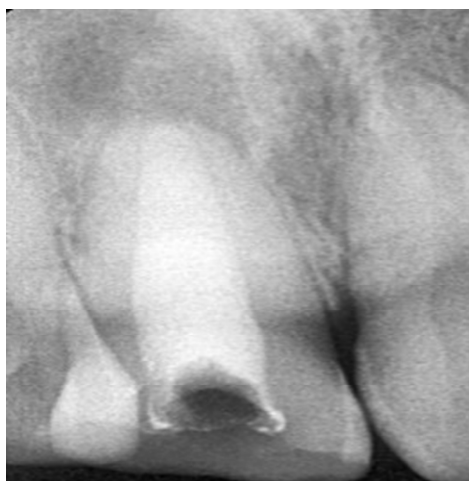**Fig. 6: Preoperative Radiograph**



**Fig. 7: Working length determination**



**Fig. 8: Calcium hydroxide placed**



**Fig. 9: Post operative radiograph**

## DISCUSSION

In teeth with incompletely formed apices, induction of a calcified apical barrier with long-term intracanal calcium hydroxide medication, used to be the most common technique for inducing biological sealing<sup>9,10</sup>. Apexification is supposed to create an environment to permit deposition of periodontal tissues to continue root development. However, the conventional apexification material Ca(OH)<sub>2</sub> has shown inherent disadvantages such as variability in treatment time, unpredictability of apical closure, difficulty in patient follow-up, failure in controlling infection, recurrence of infection, cervical fracture, and increased risk of root fracture.<sup>11,12</sup> MTA has superior biocompatibility and it is less cytotoxic and presence of calcium and phosphate ions results in attraction of blastic cells and promotes favorable environment for cementum deposition<sup>13,14</sup>

The major advantage of MTA is that unlike calcium hydroxide MTA doesn't require long treatment duration, and it has less leakage and better antibacterial properties with setting time of 3-4 hours with a Ph of 12.5. MTA acts by producing interleukins and cytokines release which leads to the formation of hard tissue.<sup>15,16</sup>

However, apexification with MTA apical plug requires specific facilities such as points and carriers to facilitate its insertion, and correct adaptation within the ideal apical limit may be more difficult in extremely large foramina. Nevertheless, studies have reported that the MTA placement technique using passive ultrasonic vibration can improve the marginal adaptation of the material<sup>17</sup>. Moreover, the surgical microscope enables increased lighting and makes viewing and insertion of the MTA easier, although radiographic confirmation at this stage cannot be overlooked.

## CONCLUSION

MTA has numerous applications in endodontic therapy that range from apexification to pulpotomy. The primary advantages of this material as an apical barrier include development of proper apical seal and excellent biocompatibility. Single visit apexification with a novel biocompatible material like MTA is a new boon in effective management of teeth with open apex. This innovative procedure is predictable and less time consuming one.

## REFERENCES

1. **De Jesus Soares A, Yuri Nagata J, Casarin RC, Flavio Affonso de Almeida J, Gomes BP, Augusto Zaia A, Randi Ferraz CC, Jose de Souza-Filho F.** Apexification with a new intra-canal medicament: a multidisciplinary case report. *Iran Endod J.* 2012;7(3):165-70.
2. **Khalilak Z, Vali T, Danesh F, Vatanpour M.** The Effect of OneStep or Two-Step MTAPlug and Tooth Apical Width on Coronal Leakage in Open Apex Teeth. *Iran Endod J.* 2012;7(1):10-4.
3. **Al Ansary MA, Day PF, Duggal MS, Brunton PA.** Interventions for treating traumatized necrotic immature permanent anterior teeth: inducing a calcific barrier & root strengthening. *Dent Traumatol.* 2009;25(4):367-79.
4. **AAE Glossary of Endodontic Terms, 7th ed, American Association of Endodontists, Chicago, 2003.**
5. **EI- Meligy OA, Avery DR.** Comparison of apexification with mineral trioxide aggregate and calcium hydroxide. *Pediatr Dent* 2006; 28: 248-253.
6. **Kratchman SI.** Perforation repair and one-step apexification procedures. *Dent Clin North Am* 2004; 48: 291-307.
7. **Shabahang S, Torbinejad M.** Treatment of teeth with wide open apices using mineral trioxide aggregate. *Pract. Periodont, Anesthest Dent* 2000; 12: 315-320
8. **Mitchell PJ, Pitt-Ford TR, Torabinejad M, et al.** Osteoblast biocompatibility of mineral trioxide aggregate. *Biomaterials* 1999; 20: 167-173.
9. **Frank AL.** Therapy for the divergent pulpless tooth by continued apical formation. *J Am Dent Assoc.* 1966;72(1):87-93.
10. **Morse DR, O'Larnic J, Yesilsoy C.** Apexification: review of the literature. *Quintessence Int.* 1990;21(7):589-98.
11. **M. Maroto, E. Barber 'ya, P. Planells, and V. Vera,** "Treatment of a non-vital immature incisor with mineral trioxide aggregate (MTA)," *Dental Traumatology*, vol. 19, no. 3, pp. 165-169, 2003.
12. **J. O. Andreasen, B. Farik, and E. C. Munksgaard,** "Long-term calcium hydroxide as a root canal dressing may increase risk of root fracture," *Dental Traumatology*, vol. 18, no. 3, pp. 134-137, 2002.
13. **J. K. Weldon Jr., D. H. Pashley, R. J. Loushine, R. N. Welle, and W. F. Kimbroug,** "Sealing ability of mineral trioxide aggregate and super-eba when used as furcation repair materials: a longitudinal study," *Journal of Endodontics*, vol.

- 28, no. 6, pp. 467–470, 2002.
14. **G. De-Deus, V. Petrucci, E. Gurgel-Filho, and T. CoutinhoFilho**, “MTA versus Portland cement as repair material for furcal perforations: a laboratory study using a polymicrobial leakage model,” *International Endodontic Journal*, vol. 39, no. 4, pp. 293–298, 2006.
  15. **Ham KA, Witherspoon DE, Gutmann JL, Ravindranath S, Gait TC, Opperman LA**. Preliminary evaluation of BMP-2 expression and histological characteristics during apexification with calcium hydroxide and mineral trioxide aggregate. *Journal of Endodontics*. 2005 Apr 30;31(4):275-9.
  16. **El Meligy OA, Avery DR**. Comparison of apexification with mineral trioxide aggregate and calcium hydroxide. *Pediatric dentistry*. 2006 May 1; 28(3):248-53.
  17. **Araujo AC, Nunes E, Fonseca AA, Cortes MI, Horta MC, Silveira FF**. Influence of smear layer removal and application mode of MTA on the marginal adaptation in immature teeth: a SEM analysis. *Dent Traumatol*. 2013;29(3):212-7.